

Re-expansion Pulmonary Oedema

Mahajan GN^a, Sangeetha E^a, CP Rauf^a

a. Department of Respiratory Medicine, Chest Hospital, Calicut.*

ABSTRACT

Published on 30th September 2008

Re-expansion pulmonary oedema is a rare entity, reported incidence being 0.9 % after drainage of pneumothorax or pleural effusion. Though easily recognizable clinically and radiologically, and not difficult to treat, the mortality may occur even in previously healthy young individual. Here we are reporting a case of re-expansion pulmonary oedema which we recently came across and treated successfully.

Keywords: Re-expansion pulmonary edema

*See End Note for complete author details

CASE

A 48 yrs old male came with history of breathlessness and right sided chest pain of 15 days duration. The breathlessness was on exertion without wheeze, palpitation. Chest pain was dull aching in quality and patient was unable to walk few metres without becoming breathless. There is no history of pulmonary tuberculosis. He is non-diabetic, non-hypertensive. He is an ex-beedi smoker with 10 pack-yr. history of smoking. He stopped smoking 3 yrs back. He consulted a general practitioner who diagnosed that he has pneumothorax on the right following chest X-ray and he was observed for 1 week. As the pneumothorax, was not improving, the patient was referred to our care. (Date : 1/9/07)

On examination, patient was in no apparent distress and he was afebrile, pulse 110/min regular, respiratory rate 30/min. BP 130/80 mmHg. O₂sat : 95% in room air, no pallor, cyanosis, clubbing, icterus, lymphadenopathy or pedal oedema. JVP was normal. On respiratory system examination, Trachea was central, apex beat in left 5th intercostal space in mid-clavicular line. Respiratory movements were diminished on right side, Vocal fremitus diminished, percussion note hyper-resonant, breath sounds were diminished in the right infrascapular, mammary, axillary areas. Other systems normal.

X ray chest postero-anterior view was done (9.42 p.m.) which showed right pneumothorax. Tube thoracostomy was done (10.10 p.m.) in right mid-axillary line in 5th intercostal space. Following tube

thoracostomy, initially. O₂sat (10.20 p.m.) improved to 98 % but later patient developed mild cough and saturation dropped to 92 % (time 10.30 pm) and his pulse became low volume BP 80/60 skin cold and clammy.

Patient was shifted to ICU, O₂ inhalation, nebulizer bronchodilators and normal saline infusion given. No diuretic used. On auscultation now there were fine crepitations in the expanded lung. Diagnosis of re-expansion pulmonary oedema was made (10.45 pm). Post procedure Xray done ; which showed extensive consolidation right lung. (11.00 p.m.) Diagnosis of re-expansion pulmonary oedema confirmed, patient was treated with bronchodilator, intravenous fluids non invasive ventilation. Patient improved by 12.00

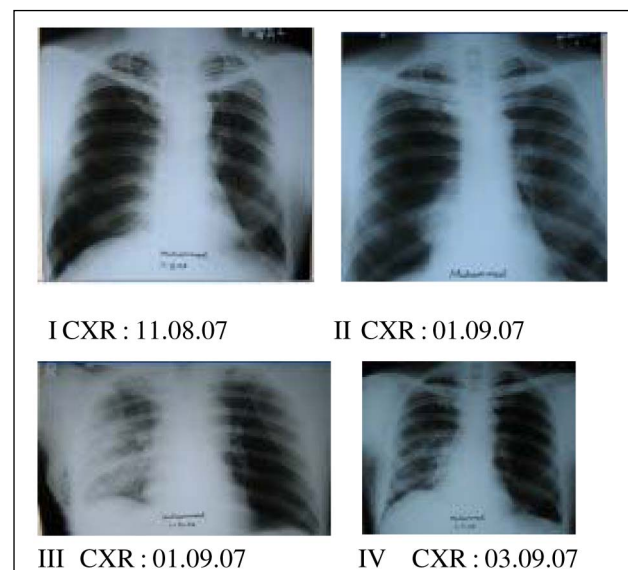


Figure 1. Immediately after tube thoracostomy

Corresponding Author:

Dr. C P Rauf, Chief, Department of Respiratory Medicine, Chest Hospital, Calicut.
 Email: cprauf@dataone.in

mid-night with saturation 97 % and by 2.00 a.m. saturation was 99 % with oxygen 2 liter/min.. Later hospital stay was uneventful and intercostal tube was removed four days later and patient was discharged.

CASE DISCUSSION

Re-expansion Pulmonary oedema is a rare entity. It is first described by Foucart in 1875.¹ Reported incidence of Re-expansion pulmonary oedema is 0.9% in the patients who has been treated with intercostal tube drainage for spontaneous pneumothorax or for evacuation of pleural effusion.² Occasionally it may occur following removal of misplaced endotracheal tube. Exact mechanism for re-expansion pulmonary oedema is controversial; it results probably because of increased capillary permeability due to raised trans-pulmonary pressure. Or it may be due to pulmonary micro-vascular injury by oxygen free radicals or other substances produced due to hypoxic lung injury which occurs during lung collapse or decreased surfactant in the collapsed lung. Presentation is asymptomatic or the patient may present with cough and increased dyspnoea² or features of shock. Occasionally bilateral pulmonary oedema has been reported.⁵

This diagnosis has to be entertained in any patient who goes into shock following tube thoracostomy done for pneumothorax or pleural effusion; and by clinical & radiological examination.

Management: Correction of hypoxemia and hypovolemia, and inotropic support is required in most cases. Severe cases may require mechanical ventilation.⁶

It is important to understand that hypovolaemia due to sudden shifting to intravascular lung water to the pulmonary interstitium is the cause of pulmonary

oedema and treatment is to rehydrate the patient with IV Saline. Diuretics have no rational role in this type of pulmonary edema.

Prognosis: In one study mortality has been reported in 21 % of Cases⁵ though real incidence must be very low because mild cases may not be reported. Mortality occur due to severe hypoxemia, usually within first 24-48 hours of development of re-expansion pulmonary oedema. If patient survives this period, recovery is usually complete.⁵

END NOTE

Author Information

1. Dr. Mahajan GN, DNB Resident, Department of Respiratory Medicine, Chest Hospital, Calicut
2. Dr. Sangeetha E, Junior Consultant, Department of Respiratory Medicine, Chest Hospital, Calicut
3. Dr. CP Rauf, Chief, Department of Respiratory Medicine, Chest Hospital, Calicut

Conflict of Interest: None declared

Cite this article as: Mahajan GN, Sangeetha E, CP Rauf. Re-expansion Pulmonary Oedema. Kerala Medical Journal. 2008 Sep 30;1(1):28-29

REFERENCES

1. Re-expansion Pulmonary edema. Chest 75: 192- 194, 1979.
2. Re-expansion pulmonary edema following spontaneous pneumothorax.. Rozenman J & Colleague, Resp. Med. 90:235, 1996
3. Role of free radicals in Pathogenesis of reexpansion. Jackson RM & Colleague-AM Rev. Respir.Dise 137:1165,1988
4. Experimental evaluation of re-expansion-pul. edema. Ewell RW & Colleague. Ann Thorac Surg.26:126, 1978.
5. Mahfood S, Hix WR, Aaron BL, Blaes P, Watson DC. Reexpansion pulmonary edema. Ann Thorac Surg. 1988 Mar;45(3):340-5.
6. Treatment of life-threatening re-expansion pulmonary edema. Wong CF and Colleagues Resp. Med 85: 69,1991