

Interstitial Pneumonia in Chikungunya Infection

M Kuriakose^a, Regi Paul^b, Anver^a

a. Department of Medicine, MOSC Medical College Kolenchery; b. Department of Community Medicine, Dr. SMCSI Medical College.*

ABSTRACT

Published on 30th September 2008

We are reporting a case of Chikungunya in a 39 year old female who was investigated for fever and arthralgia. She had no respiratory symptoms or breathlessness. Her chest x ray showed diffuse interstitial infiltration reported as viral interstitial pneumonia by the radiologist. Interstitial pneumonia was self-limiting and cleared in two weeks time with no treatment except chloroquin. No underlying illness except Chikungunya was identified.

Keywords: Fever and arthralgia, Chikungunya symptoms, Chikungunya diagnosis and management.

*See End Note for complete author details

SUMMARY

We are reporting a case of Chikungunya in a 39 year old female who was investigated for fever and arthralgia. She had no respiratory symptoms or breathlessness. Her chest x ray showed diffuse interstitial infiltration reported as viral interstitial pneumonia by the radiologist. Interstitial pneumonia was self-limiting and cleared in two weeks time with no treatment except chloroquin. No underlying illness except Chikungunya was identified.

INTRODUCTION

Chikungunya is an acute febrile illness caused by a single stranded RNA virus belonging to family Togaviridae, genus Alpha¹ (CHIK Virus). The natural hosts are nonhuman primates and transmission is by Aedes mosquito. It was reported first in Tanzania, Africa in 1952 and is endemic in subSaharan Africa. The disease has made inroads into Asia and is now endemic in most of India, Indonesia and Philippines (map).

Several outbreaks were reported from the southern Indian states of Kerala, Tamil Nadu, Karnataka and Andhra Pradesh in 2005 and 2006.²

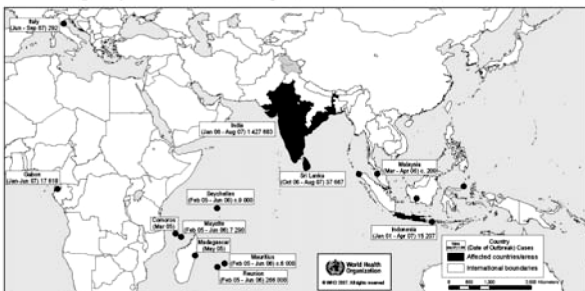
The clinical presentation is sudden with fever and migratory polyarthritits mainly affecting small peripheral joints of limbs. Fever settles in 3-6 days and a nonspecific rash may appear as the fever subsides. Arthralgia and arthritis continue long after this in older patients sometimes years. Chikungunya is considered a nonfatal infection. However in 2005-2006, 200 deaths were associated with Chikungunya in the French Reunion island. Out breaks in the southern Indian states of Kerala, Tamilnadu, Karnataka and Andhra Pradesh were reported to be associated with several deaths. 125 deaths were attributed to Chikungunya in Kerala during 2005-2006.³ Death following Chikungunya is generally attributed to exacerbation of chronic diseases affecting vital organs like brain, kidneys and heart.

CASE REPORT

39 nine year old Mrs. MB visited our outpatient department on 09/07/07 with three days history of fever, tiredness and painful swelling of peripheral limb joints. Fever started suddenly, was high grade and associated with chills. She had severe body ache and pain in all peripheral joints on movement.

She had a similar episode of fever and severe joint pain one month before the present episode. Patient consulted her family physician who diagnosed Chikungunya and gave her diclofenac and piroxicam. Fever and pain became less intense in three days but continued to wax

Chikungunya Outbreak reported countries, October 2007



Source(s): - World Health Organization (WHO)

Figure 1. Map

Corresponding Author:

Dr. M Kuriakose, Professor of Medicine, Department of Medicine, MOSC Medical College, Kolenchery
E-mail: imaksb@yahoo.co.in

and wane in an intermittent pattern. She took analgesics as and when joint pain became troublesome. She came to the hospital this time because the symptoms were more severe. She gave no history of any chronic illness before this.

On examination she complained of severe body ache and malaise. She was not breathless All peripheral joints of all four limbs were tender and painful on movement, but no synovial thickening or effusion was present.

BP=110/70 mmHg Pulse= 84/min, Temperature= 100.4, F Respiratory rate=26/min There was no respiratory distress.

System examination showed no abnormal physical findings. She was admitted for investigations and observation.

Investigations

Haemoglobin	-	10.7gm%
WBC total Count	-	8200/cmm
Differential count		
neutrophils (%)	-	73
Lymphocytes (%)	-	16
Monocytes (%)	-	2
Eosinophils (%)	-	7
Basophils (%)	-	1
Band forms (%)	-	1
ESR (mm/1st hour)	-	104
Platelet	-	276000/cmm
Urine routine	-	normal
Creatinine	-	0.7mg/dl
SGPT	-	43 IU/L
C reactive Protein	-	3+

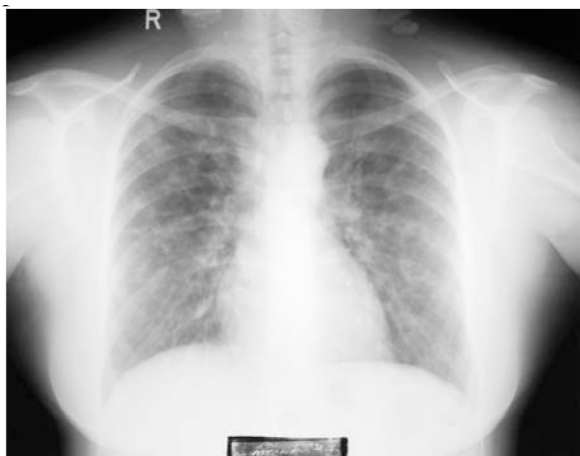


Figure 2. CXR on 09/07/07

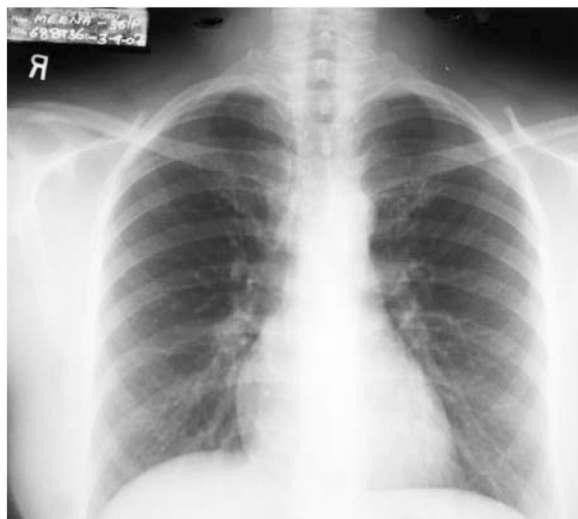


Figure 3. CXR on 07/09/07

RA factor	-	negative
Anti Nuclear Antibodies	-	Negative
Anti ds DNA Antibody	-	53.86IU/ml (N <117)
Total plasma Protein	-	8.4gm/dl
Albumin	-	4.3gm/dl
Globulin	-	4.1gm/dl

X-Ray of chest on 09/07/07 showed prominent vascular and interstitial marking in both lung fields consistent with interstitial pneumonia. No pleural effusion or cardiomegaly was noted (figure 2). Blood for anti CHIK IgM antibody was sent to National Institute of Virology, Pune was reported positive.

MANAGEMENT

Patient was monitored for any respiratory distress. She was given Hydroxy Chloroquin Sulphate (HCQS) 200mg twice daily. She became symptomatically better, fever and joint pain subsided in a few days. HCQS was continued for two weeks more and stopped. Fever or arthralgia did not recur.

Patient was followed up weekly for a month. She continues to be well.

Chest x-rays taken on 19/07/07 and 07/09/07 showed complete clearing of interstitial shadows (figure 3) Erythrocyte Sedimentation Rate (ESR) was 15mm at 1 hour on 19/07/07

DISCUSSION

Chikungunya outbreaks have been reported from different parts of India since 1963.² Cases are being

reported from the state of Kerala from 2005. There was an epidemic of acute fever cases in the southern and central districts of Kerala during the southwest monsoon of 2007. The reported number of persons confirmed to have Chikungunya was 7000 while number of suspected cases was much higher. 50 deaths were associated directly or indirectly with Chikungunya infection.³ Most of the deaths were reported in elderly and chronically ill patients. The role of the CHIK virus in these deaths is being debated. Cases of leptospirosis, dengue fever or other acute infections may have been overlooked in some of these cases.

Chikungunya is a systemic infection where the major manifestation is arthritis. Thrombocytopenia and slight rise in liver enzymes may be noted. Neurological complications have like meningo-encephalitis have been reported in Indian & Reunion island out breaks of Chikungunya recently; other system involvement is said to be negligible.⁴ We have not come across any reports of interstitial pneumonia associated with Chikungunya in the literature. However the virus causing direct damage to vital organs like lungs cannot be dismissed without further studies. Genome analysis of CHIK virus that spread in Kerala in 2007 has revealed a genomic shift at E1:A226V. Such point mutations can significantly alter epidemic potential and virulence of the virus.⁵

The interstitial pneumonia in this patient was asymptomatic except for mild tachypnoea. Clinical and laboratory tests did not reveal any other infection or connective tissue disorder. Anti Chikungunya IgM antibody test was unequivocally positive. Clinical and radiological improvement was noticed within a few days with no treatment except chloroquin. These facts strongly point to Chikungunya as the causative factor. Exacerbation of symptoms with low grade fever, arthralgia and interstitial pneumonia occurred 3 weeks after the initial fever. So an inappropriate immune response or viral persistence is likely to be the cause of this. Further clinical and virological studies are indicated in this regard as new cases present in future.

Rapid recovery in this patient may have been because she is young and was previously healthy. If interstitial pneumonia occurs in elderly persons with underlying lung diseases respiratory failure is more likely to follow.⁶ Awareness of potentially fatal complications of CHIK infection is essential to help us detect them. Monitoring of vital organ functions and intervention when indicated are necessary in Chikungunya patients in acute phase as well as immune phase.

The Indian Medical Association and NIV Pune have confirmed that the predominant agent of the monsoon epidemic in Kerala was indeed the Chikungunya virus. The vector *Aedes aegypti* mosquito has firmly established itself in Kerala and their population escalates during the monsoon months of June to September. Dengue fever, caused by yet another arbovirus transmitted by *Aedes aegypti*, has become endemic in Kerala. Yellow Fever, transmitted by the same mosquito and with very high mortality rate may make its entry into the area through international travel. Vector control by elimination of breeding sites is urgently needed.

END NOTE

Author Information

1. Dr. M Kuriakose, Professor of Medicine, Department of Medicine, MOSC Medical College, Kolenchery
2. Dr. Regi Paul, Assistant Professor, Department of Community Medicine, Dr.SMCSI Medical College
3. Dr. Anver, Senior Resident, Department of Medicine, MOSC Medical College, Kolenchery

Conflict of Interest: None declared

Acknowledgement

We gratefully acknowledge the technical assistance extended by Mr. Shibu Joseph & Ms Shiji George.

Cite this article as: M Kuriakose, Regi Paul, Anver. Interstitial Pneumonia in Chikungunya Infection. Kerala Medical Journal. 2008 Sep 30;1(1):25-27

REFERENCES

1. Clarence J Peters:- Infections caused by Arthropod and Rodent borne viruses in chapter 180 volume I Harrison's Principles of Internal Medicine 16th Edn. Page 1168 Editors Kasper D. L, Braunwald E, Fauci A.S, Hauser S L, Longo D. L, Jameson J. L, McGraw- Hill Medical publication division New York.
2. S.P Kalantri, Rajnish Joshi, Lee W Riley Review Article in National Medical Journal of India Vol 19 No. 6 2006 page 315-322.
3. Chikungunya-Wikipedia.
4. Ravi V. Re-emergence of Chikungunya virus in India. Indian Journal of Medical Microbiology. 2006;24(2):83.
5. Santhosh SR, Dash PK, Parida MM, Khan M, Tiwari M, Lakshmana Rao PV. Comparative full genome analysis revealed E1: A226V shift in 2007 Indian Chikungunya virus isolates. Virus Res. 2008 Jul;135(1):36-41.
6. 6.15 days, 14,000 cases; Chikungunya unchecked Ahmedabad.com September 16, 2006.