

Clinico-Pathology Study of Vitellointestinal Remnants in Children

R Rajendran^a, Sudin V Daniel^a, NS Noor Sathar^a, Anju Susan Varghese^a

a. Department of Pediatric Surgery, S.A.T. Hospital, Government Medical College, Thiruvananthapuram-11, Kerala.*

ABSTRACT

Published on 30th September 2008

Background & Aim: Persistence of vitellointestinal duct can manifest in different ways. Aim was to analyse the age and sex incidence, symptomatology, preoperative diagnosis, operative findings, postoperative complications, histological findings and associated congenital malformations of vitellointestinal remnants in children.

Methods: Retrospective study of hospital records for 30 years in a tertiary care centre. The data based on proforma was collected and analyzed. The findings were compared with similar published data.

Results: 165 cases were analysed. Meckel's diverticulum was most frequently found in 0-2 year age group, with a male : female ratio of 2.8 :1. The ratio of symptomatic to asymptomatic cases was 4:1. Intestinal obstruction was the most common preoperative diagnosis and accounted for the majority of cases at operation. Vitellointestinal band causing external compression was the commonest cause of obstruction. Volvulus of the intestine due to such band was the second and intussusception was the third cause of obstruction, in which Meckel's diverticulum was the lead point in 36%. Meckel's diverticulitis was the next common operative diagnosis (25%). Bleeding per rectum was the manifestation in 13% cases. On histopathologic examination of Meckel's diverticulum, ectopic gastric tissue was found in 10% cases. A number of congenital anomalies were identified to co-exist with Meckel's diverticulum. The mortality rate was 6.6%.

Conclusion: Meckel's diverticulum is the commonest anomaly of persistent vitellointestinal duct. Intestinal obstruction, diverticulitis, and bleeding per rectum are the commonest presentations in contrast to intestinal obstruction, bleeding per rectum followed by diverticulitis as found in some other studies.

Keywords: Vitellointestinal remnant, Meckel's diverticulum, Intestinal obstruction, Vitellointestinal band, Intussusception, Meckel's diverticulitis, Bleeding P.R., Ectopic gastric tissue, Ectopic pancreatic tissue.

*See End Note for complete author details

INTRODUCTION

Vitellointestinal duct (V.I.D)/ omphalomesenteric duct (O.M.D) connects the yolk sac with the primitive midgut of fetus and it passes through the umbilicus. The vitelline duct fuses with the body stalk to form the umbilical cord. Regression of VID normally occurs between 5th and 7th week of intrauterine life.¹ Failure of complete obliteration of VID can result in remnants and their symptoms. There are several anatomical variants of persistent vitellointestinal remnant.

Meckel's diverticulum (MD) is by far the most common anomaly. It is the most common congenital anomaly of the gastrointestinal tract. Two recent studies report an incidence of 2% in the general population.^{2,3} It is situated in the antimesenteric border of small intestine, about 60 cms from ileocaecal valve and is usually 3-5 cm long (2 percent - 2 feet - 2 inches is a useful aide memoire). Meckel's diverticulum is true diverticulum, in

which all three intestinal layers are present^{4,5,6} and has its own blood supply. The tip is free within the peritoneal cavity in 74% of cases. Remnants of left vitelline artery (which usually involutes) or of vitellointestinal duct may persist and attach it to anterior abdominal wall. Meckel's diverticulum occurs with equal frequency in both sexes, but symptomatic diverticula occur more commonly in males.⁷ They are prone to different types of complications. The commonest complications are lower gastrointestinal bleeding, intestinal obstruction, and inflammatory complications. In 20% cases, mucosa contains heterotopic epithelium namely gastric, colonic or pancreatic tissue. Presence of heterotopic gastric and pancreatic tissue in the diverticulum is responsible for the bleeding and inflammation.⁸ Vitellointestinal remnants that attach the ileum with the umbilicus can cause extrinsic compression and obstruct the bowel. It can also cause volvulus of the intestine. Intussusception is a common cause of intestinal obstruction;

Corresponding Author:

Dr. R Rajendran, Director, Consultant Pediatric Surgeon & General Surgeon R.R.Children's Hospital & Surgical Centre, Attinkuzhy, Near Technopark, N.H.Bye Pass, Kazhakkuttom P.O, Thiruvananthapuram - 695 582, Kerala.
Email : rrajendr@asianetindia.com

Meckel's diverticulum can act as a lead-point for intussusception. Most Meckel's diverticulae are clinically silent.⁹ The life-time risk for complications of Meckel's diverticulum is 6.4%.¹⁰ All symptomatic diverticula have to be resected.¹¹ Whether an asymptomatic, incidentally discovered diverticulum should be removed or not remains controversial.

We analysed the age and sex incidence, symptomatology, investigations, preoperative diagnoses, operative findings, histological findings and other associated congenital anomalies in children with persistent VID in our department.

MATERIALS AND METHODS

Retrospective study of hospital records from 1971 to 2000 of department of Pediatric surgery, S.A.T Hospital, Govt. Medical College, Trivandrum was done. Records of children who had undergone laparotomy in whom Meckel's diverticulum or some anatomical variant of the vitellointestinal duct remnant was found were included in the study. The data was entered into proforma and analysed. The results were compared with those of similar studies published.

RESULTS

165 cases were entered into study.

Age incidence: Meckel's diverticulum was most frequently found in the 0–2 years age group, accounting for 49% (81/165). Children in the 2-4 years age group comprised of 15% (25/165) and 10-12 years age group of 10% (17/165).

Sex incidence: Males outnumbered females (2.8:1) in all age groups.

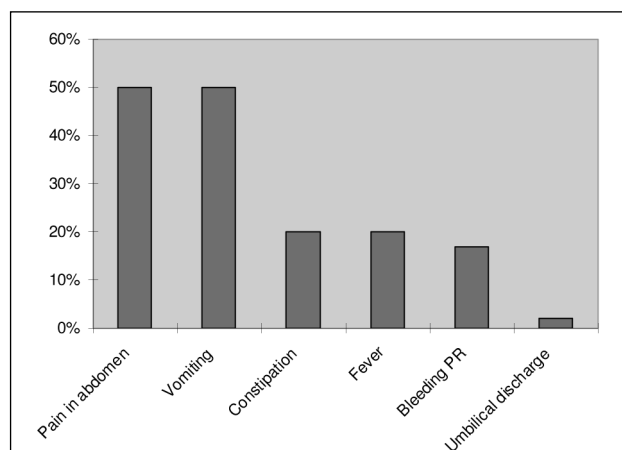


Figure 1. Clinical presentation of vitellointestinal duct remnants

Clinical presentation

Out of 165 cases, 133 were symptomatic while 32 were asymptomatic Meckel's diverticula detected at laparotomy for some other indications. Thus the ratio of symptomatic to asymptomatic cases was 4:1 (133/32). Vomiting (50% cases), pain abdomen (50%), abdominal distension (49%), visible peristalsis (30%), mass abdomen (17%), were the common presentations. Bleeding per rectum (in the form of melaena/ blood on fingers on per rectal examination) was found in 13% cases. Umbilical discharge was found in 4% cases (figure 1).

Investigations which contributed to preoperative diagnosis were a) plain x-ray examination of abdomen (diagnosed intestinal obstruction / pneumoperitoneum) b) fistulogram (identified patent vitellointestinal duct) c) Meckel's scan using technetium 99m pertechnetate to diagnose Meckel's diverticulum (figure 2) d) sigmoidoscopy in cases of lower G.I.bleeding.

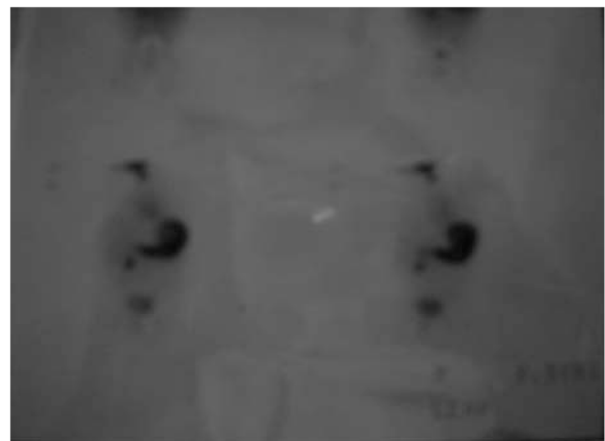

Figure 2. Meckel's scan showing concentration of radiopharmaceutical in the Right iliac fossa and in the urinary bladder. A case of bleeding Meckel's diverticulum with ectopic gastric mucosa

Preoperative diagnosis

Acute intestinal obstruction was the most common preoperative diagnosis, accounting for 50% (67/133). This was followed by intussusception in 15% cases (20/133), appendicitis in 15% cases (20/133) and lower gastrointestinal bleeding in 13% (17/133) cases, patent vitellointestinal duct in 5% (7/133) cases, and obstructed hernia in 1.5% (2/133).

Operative findings

Intestinal obstruction due to various causes was the most common finding. Vitellointestinal band (cord like remnant attaching the ileum or the tip of a Meckel's diverticulum with the umbilicus), causing extrinsic compression and intestinal obstruction was the

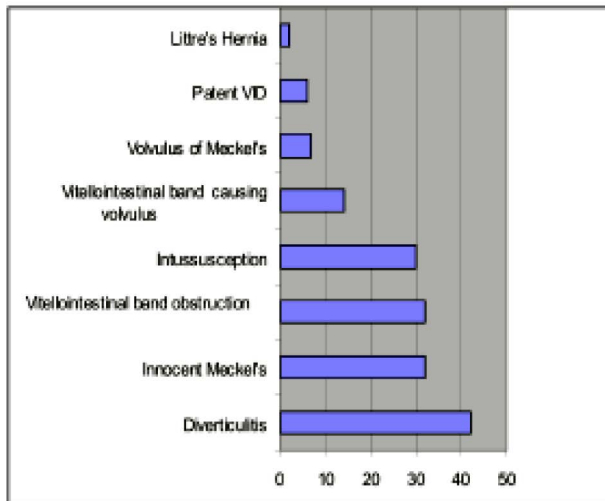


Figure 3. Operative findings in cases of vitellointestinal remnants in children

commonest (19%) (31/165). Volvulus of the ileum due to vitellointestinal band was the cause of obstruction in 17.5%, (29/165), and intussusception in 9% (15/165) of which Meckel's diverticulum formed the lead-point in 7 cases (47%). Torsion of the Meckel's diverticulum caused intestinal obstruction in 5% (8/165) cases. Litre's hernia was the least common cause of intestinal obstruction; it accounted for 1.2% (2/165) cases. The incidence of gangrene in Meckel's with or without that of adjacent ileum was 24%. Perforation was seen in 18%. Next to intestinal obstruction, Meckel's diverticulitis was found in 25% (40/165) cases, followed by patent vitellointestinal duct (5/165 cases) and umbilical cysts (3/165 cases). Rest 32 of 165 cases had normal Meckel's diverticulum at operation (figure 3).

Operative procedure

Wedge resection of Meckel's diverticulum was the common procedure done (52%). Resection of a segment of ileum bearing the diverticulum and end-to-end anastomosis was done in 48% cases.

Post operative complications

Author	No. of cases	Intestinal obstruction	Bleeding	Diverticulitis	Heterotopic Mucosa
Oguzkurt ¹⁸ (2001)	92	48.9%	19.5%	11.9%	30.4%
Ma Y ²⁰ (1998)	65	23%	43%	24% (Peritonitis)	65.3%
Marinaccio ²¹ (1997)	7	4 (Intussusception)	3	1	-
Ruiz Orrego ²² (1995)	101	47.4%	15.8%	19.7%	20.7%
Present study	133	46.6%	13%	30%	16.54%

During the period of hospital stay, which ranged from 10 days to 3 months, the most common postoperative complication was minor wound infection 10% (16/165). Major wound infections which required secondary suturing accounted for 5% (8/165) cases. 4 cases developed faecal fistula, out of which one died. Complicated Meckel's diverticulum had a morbidity rate of 23%, and a mortality rate of 6.6%.

HISTOLOGICAL FEATURES

Total cases with heterotopic mucosa were 22/133 (16.54%). Heterotopic gastric tissue was found in 14/133 cases (10.5%), pancreatic tissue in 5/133 cases (3.76%) and both gastric and pancreatic tissue in 3/133 cases (2.25%). Rare histological features were, one case of lymphoma and one case of granulomatous lesion (tuberculosis).

Congenital anomalies associated with Meckel's diverticulum were as follows.

1. Gastroschisis and malrotation
2. Exomphalos minor and V.I band
3. Exomphalos minor
4. Elephant trunk deformity
5. Exomphalos major, liver cysts, short left colon
6. Diaphragmatic hernia
7. High ARM, Bifed Scrotum, Hypospadias
8. Polydactyly and hypotonia &
9. E-minor, Monogolism & V.I.fistula
10. Exomphalos minor & B/L CTEV
11. Jejunal atresia
12. Umbilical hernia and Low arm
13. Annular pancreas & malrotation
14. Hirschprung's disease and patent VID
15. E-minor, cleft lip, cleft palate, polydactyly
16. E-major, high ARM, jejunal atresia

DISCUSSION

Failure of complete obliteration of VID can result in one of the following anomalies.⁸

- a) Meckel's diverticulum
- b) Meckel's diverticulum with a band connecting its tip to the body wall
- c) A cyst within the cord connecting the Meckel's diverticulum to the abdominal wall
- d) A fibrous cord extending from the ileum to the abdominal wall (obliterated vitelline vessels)
- e) Patent VID (omphaloileal fistula)

f) Umbilical sinus : represents an external vestige of vitelline duct. g) umbilical polyps. Of these, Meckel's diverticulum is the commonest anomaly. It remains unattached in 74% of cases. The vast majority of Meckel's diverticula are asymptomatic.

Most common clinical presentations of Meckel's diverticulum are lower gastrointestinal bleeding, intestinal obstruction and inflammatory complications. The bleeding is usually painless, in children younger than 5 years. It can present as melaena or haematochezia. It is frequently episodic and sometimes massive. Intestinal obstruction due to VID remnants can be caused by intussusception, by cord-like remnants, torsion of Meckel's diverticulum, ileal knotting by a long diverticulum that itself formed a knot and by Littre's hernia. Inflammation of Meckel's diverticulum is usually peptic. Less than 10% of persistent VID may present with umbilical abnormalities.

About one half of cases of persistent VID manifested before the age of 2 years in our series as usual in other reports. Male sex predominated in symptomatic VID which also goes well with other reports. The findings in this study that 32 of the total 165 cases had normal Meckel's diverticulum puts the ratio of symptomatic to asymptomatic cases as 4:1. Intestinal obstruction was the commonest presentation on our series; this was followed by cases with inflammation. Lower G.I bleeding was the manifestation in 13% of symptomatic patients. The commonest cause of intestinal obstruction was reported as intussusception in 46% cases, followed by volvulus in 24%.¹ In a study from Turkey,¹² the indications for surgical removal of MD were intestinal obstruction (48.9%), diverticulitis (11.9%) and bleeding (19.5%) in the order of frequency. Heterotopic gastric mucosa was detected in 29 of 92 (30.4%) patients of whom 8, 3 and 16 presented with intestinal obstruction, diverticulitis and bleeding respectively. This study also concluded that the presence of *Helicobacter Pylori* (HP) colonisation in heterotopic gastric mucosa does not increase the likelihood of rectal bleeding. Most studies have detected that intestinal obstruction is the most frequent complication of Meckel's diverticulum (Table 1). In an analysis of 61 children in Mexico city during a period of 10 years,¹³ in infants the main clinical finding was rectal bleeding; intestinal occlusion was the most common clinical expression in older children. Gastric mucosa was a common finding in diverticulum of children with rectal bleeding in contrast to ileal mucosa in children with intestinal occlusion. Also the best method for diagnosis is ^{99m}Tc-pertechnetate scanning. Ileal obstruction caused by a ring

like lipovascular mesenteric band (mesodiverticular band) encroaching externally on the lumen resulting in formation of phytobezoar has been reported.¹⁴

The rare presentations of persistent VID in our series were patent VID (omphaloileal fistula) (5/132 cases) and umbilical cysts (3/132 cases). Some rare presentations of VID are reported in literature. Congenital appendico-umbilical fistula is due to patent omphalomesenteric duct of the vermiform appendix.¹⁵ Exomphalos and vitellointestinal ducts remnants are well-known entities. Congenital fistulation of a Meckel's Diverticulum to the surface of an exomphalos minor was reported by Hale.¹⁶ Other rare complications of Meckel's diverticulum include long-standing history of black stools and progressive pallor due to iron deficiency anaemia,¹⁷ Cystic Meckel's diverticulum as a cause of pelvic mass presenting with recurrent urinary infection,¹⁸ and Meckel's diverticulitis due to impacted *Tenia Saginata*.¹⁹ The likelihood of finding heterotopic mucosa depends on whether the Meckel's diverticulum is discovered incidentally or is symptomatic. Symptomatic patients had high incidence of heterotopic mucosa. Fifteen percent of the asymptomatic patients and 54% of the symptomatic patients had heterotopic mucosa in the diverticulum;⁸ predominantly (65% to 90% of patients) gastric mucosa and less commonly (about 5% of patients) had heterotopic mucosa. In our series of symptomatic patients the incidence of heterotopic mucosa was much lower (16.54%), when compared to other series (Table 1). Serious unexpected histologic diagnoses like lymphoma and granulomatous lesion are very peculiar and such findings stress the need for histopathologic examination of resected Meckel's diverticula. Abnormal hypercellular/heterotopic ganglia (HHG) which were histomorphologically similar to those found in intestinal neuronal dysplasia type B (IND – B) were found in omphalomesenteric duct remnants.²³ The overrepresentation of HHG in symptomatic patients suggests an association with bowel obstruction. Two cases of intussusception with heterotopic pancreatic tissue as the lead-point without a Meckel's diverticulum has been reported, and the authors have proposed that the lesion was vitellointestinal tract origin.²⁴ Management of asymptomatic diverticula.^{8,22} Population based study has assessed the maximum life-time risk of complications as 6.4%. The higher morbidity and mortality associated with complicated versus incidental diverticulectomy led the authors to recommend routine incidental Meckel's diverticulectomy. Resection is clearly indicated in patients with palpable thickening in the diverticulum that is consistent with heterotopic mucosa. Unexplained

abdominal pain, and in patients with VID remnants attached to abdominal wall are also indications for resection. But resection is contraindicated in older patients and patients with risk for infection and in gastroschisis.

CONCLUSION

The present study showed significant differences in the symptomatology and complications of Meckel's diverticulum when compared with earlier studies. Intestinal obstruction was the commonest presentation in our series unlike bleeding PR in other series. The percentage of heterotopic mucosa was less in our series compared to other series. The high morbidity and mortality associated with complicated Meckel's diverticulum warrants resection of asymptomatic Meckel's diverticula found incidentally at laparotomy.

END NOTE

Author Information

1. Dr. R Rajendran, M.S, M.Ch, D.N.B, FICS, FIAMS Formerly Assistant Professor, Department of Pediatric Surgery, S.A.T. Hospital, Government Medical College, Thiruvananthapuram-11, Kerala.
2. Dr. Sudin V Daniel, M.S, DNB, Formerly M.Ch Trainee, Department of Pediatric Surgery, S.A.T. Hospital, Government Medical College, Thiruvananthapuram-11, Kerala.
3. Dr. N S Noor Sathar, M.S, M.Ch, Formerly Professor & Head, Department of Pediatric Surgery, S.A.T. Hospital, Government Medical College, Thiruvananthapuram-11, Kerala.
4. Dr. Anju Susan Varghese, Formerly House Surgeon, Department of Pediatric Surgery, S.A.T. Hospital, Government Medical College, Thiruvananthapuram-11, Kerala.

Conflict of Interest: None declared

Acknowledgement

We thank the Superintendent, S.A.T Hospital and the present Head of department of Pediatric Surgery, S.A.T. Hospital, Medical College, Trivandrum for permitting us to publish the data.

Cite this article as: R Rajendran, Sudin V Daniel, NS Noor Sathar, Anju Susan Varghese. Clinico-Pathology Study of Vitellointestinal Remnants in Children. Kerala Medical Journal. 2008 Sep 30;1(1):14-19

REFERENCES

1. Skandalakis JE, Gray SW. Embryology for surgeons, 2nd Ed. Baltimore, Williams and Wilkins; 1994.
2. Albu I et al. The ileal diverticulum: Morphoclinical and epidemiological study. Rom J Morphol Embryol 1994;39:37.
3. Matsagas MI et al. Incidence, complications and management of Meckel's diverticulum. Arch Surg 1995;130-143.
4. Sibley WL. Meckel's diverticulum : dyspepsia Meckelei from heterotopic gastric mucosa. Arch Surg 1994;29:156.
5. Soderrlund S. Meckel's diverticulum:A clinical and histological study. Acta chir, Second Suppl 1959; 248.
6. Thompson JE. Perforated Peptic Ulcer in Meckel's Diverticulum: Report of a Case Occurring Intramesenteric. Ann Surg. 1937 Jan;105(1):44-55.
7. Neil J,McC.Mortensen. The small and large intestines. In: Bailey&Loves Short Practice of Surgery, 23rd Ed.Eds. RCG Russell, NS Williams and CJK Bulstrode. London, Arnold Publishers; 2000. 1032-33.
8. St.Vil D et al. Meckel's diverticulum in children, a 20 year review. J Pediatr surg 1991 ;26: 1289.
9. Amoury RA, Snyder CL. Meckel's Diverticulum. In: Pediatric surgery Eds. James A. O'Neill Jr, Marc I Rowe, Jag L Grosfeld, Eric W Fonkalsurd, Arnold Coran. Vol 2, 5th Ed. St. Louis, Mosby; 1998.1173-84.
10. Cullen JJ et al. Surgical management of Meckel's diverticulum. An epidemiologic, population based study. Ann Surg 1994; 220: 564-568.
11. Fa-Si-Oen PR, Roumen RM, Croiset van Uchelen FA. Complications and management of Meckel's diverticulum--a review. Eur J Surg. 1999 Jul;165(7):674-8.
12. Oguzkurt P, Talim B, Tanyel FC, Caglar M, Senocak ME, Buyukpakmukcu N. The role of heterotopic gastric mucosa with or without colonization of Helicobacter pylori upon the diverse symptomatology of Meckel's diverticulum in children. Turk J Pediatr. 2001 Oct-Dec; 43(4):312-6.
13. Zarate Mondragon FE, Ramirez Mayans JA, Cervantes Bustamante R, Urquidi Rivera M, Mata Rivera N, Vargas Gomez MA et al. (Meckel's diverticulum. Study of 61 cases). Rev gastroenterol Mex. 1977 Apr-Jun; 62 (2):80-3.
14. Kleiner O, Cohen Z, Finaly R, Mordehai J, Mares AJ. Unusual presentation of omphalomesenteric duct remnant : a variant of mesodiverticular band causing intestinal obstruction. J Pediatr Surg 2000 Jul;35(7):1136-7.
15. Crankson SJ, Ahmed GS, Polkar V. Patent omphalomesenteric duct of the vermiform appendix in a neonate : congenital appendicocumbilical fistula. Pediatr Surg Int 1998 Dec; 14(3) : 229-30.
16. Hale PC, Agarwal M. Congenital fistulation of a Meckel's diverticulum to the surface of an exomphalos sac. Br J Clin Pract 1993 Sep-Oct ; 47(5) : 273.
17. Al-Onaizi I, Al-Awadi F, Al-Dawood A-L. Iron deficiency anaemia: an unusual complication of Meckel's diverticulum. Med Princ Pract. 2002 Dec;11(4):214-7.
18. Oguzkurt P, Arda IS, Kayaselçuk F, Barutçu O, Oguzkurt L. Cystic Meckel's diverticulum: A rare cause of cystic pelvic mass presenting with urinary symptoms. J Pediatr Surg. 2001 Dec;36(12):1855-8.
19. Chirdan LB, Yusufu LM, Ameh EA, Shehu SM. Meckel's diverticulitis due to Taenia saginata: case report. East Afr Med J. 2001 Feb;78(2):107-8.

20. Ma Y, Bi X, Ma D, Fan D. [Meckel's diverticulum and its complications in children]. *Hunan Yi Ke Da Xue Xue Bao*. 1998;23(6):561-2, 565.
21. Marinaccio F, Romondia A, Nobili M, Niglio F, La Riccia A, Marinaccio M. [Meckel's diverticulum in childhood. The authors' own experience]. *Minerva Chir*. 1997 Dec;52(12):1461-5.
22. Ruiz Orrego J, Rivera Medina J, Gonzales Denavides J. (Clinical characteristics of Meckel's diverticulum in a population of Children). *Rev Gastroenterol Peru* 1995 Sep-Dec;15(3):247-54.
23. Wu SS, Collins MH, Coventry S, de Chadarevian JP. Hypercellular/heterotopic ganglia in omphalomesenteric duct remnants. *Pediatr Dev Pathol*. 2001 Jun;4(3):246-51.
24. Abel R, Keen CE, Bingham JB, Maynard J, Agrawal MR, Ramachandra S. Heterotopic pancreas as lead point in intussusception: new variant of vitellointestinal tract malformation. *Pediatr Dev Pathol*. 1999 Aug;2(4):367-70.