

Anesthetic Management of Retrosternal Thyroid A Case Report

Hima Rajan^a, Anju Mariam Jacob^a

a. Department of Anesthesiology, Government Medical College, Thrissur*

ABSTRACT

Published on 15th April 2024

Airway management during thyroidectomy for retrosternal goitre is most often a challenge. It can contribute to adverse events intraoperatively and postoperatively.¹ Here we describe the anesthetic management of a patient with long standing retrosternal goitre. The patient also had compression of trachea and total thyroidectomy was advised. Patient underwent awake nasal fiber optic intubation under topical anesthesia and sedation. The entire thyroid tissue including the retrosternal thyroid was removed through the neck. This case report suggests that Awake fiberoptic intubation (FOI) under topical anesthesia can be considered in patients with retrosternal goitre. Difficult airway should always be anticipated. The success of awake intubation depends on good communication along with psychological and pharmacological preparation of the patient. The primary principle should be a patient tailored approach keeping in mind the comorbidities and clinical status of the patient.

Keywords: Airway Management, Retrosternal Goitre, Fibre Optic Intubation

*See End Note for complete author details

INTRODUCTION

Anesthetic management of patients with retrosternal extension remains a formidable challenge. This group of patients are different with respect to their evolution as well as the types, sizes and localization of retrosternal masses.² There are many ways in which vital organs in the mediastinal space may be affected. Also the respiratory and hemodynamic response to anesthesia varies among individuals. Therefore the anesthetic management of patients with retrosternal extension remains a challenge.³ There are a few case reports which illustrate acute cardiorespiratory decompensation during anesthesia due to retrosternal mass compressing the mediastinal organs which often results in life threatening conditions.⁴ Here we describe the anesthetic management of a retrosternal goiter posted for total thyroidectomy.

CASE REPORT

A 47-year-old woman weighing 67 kg presented with complaints of gradually increasing swelling in front of the neck for the past 20 years. She was on tablet

Neomercazole 10mg. She had no history of change in voice or any respiratory symptoms. She was diagnosed as a case of multinodular goitre. On examination, patient was conscious, oriented. Pulse was 88 per minute and Blood pressure was 140/80mm of Hg. ECG showed sinus rhythm. The neck swelling was firm on palpation, 10 × 4cm in size. Lower limit of the swelling was not visualized nor palpable. Airway examination showed adequate mouth opening; Mallampati score III, short neck. Indirect laryngoscopy revealed normal vocal cord mobility. Her systemic examination showed no other abnormalities.

Blood count, Renal profile and Arterial blood gas were normal. The latest thyroid function test was within normal limits. Radiological examination revealed gross tracheal shift to left. Computed Tomography (CT) showed thyroid gland with retrosternal extension up to the level of T5 vertebrae, compressing the anterior wall of trachea, deviating trachea to left and laterally extending to the submandibular space (**Figure 1**). Bronchoscopy showed extraluminal compression of posterolateral wall of trachea with luminal size around 9mm.

Cite this article as: Rajan H, Jacob AM. Anesthetic Management of Retrosternal Thyroid A Case Report. Kerala Medical Journal. 2024 Apr 15;17(1):49–51. | DOI: <https://doi.org/10.52314/kmj.2024.v17i1.633>

Corresponding Author:

Dr. Anju Mariam Jacob, Professor, Department of Anesthesiology, Government Medical College, Thrissur.
E-mail: anjumariamjacob@gmail.com

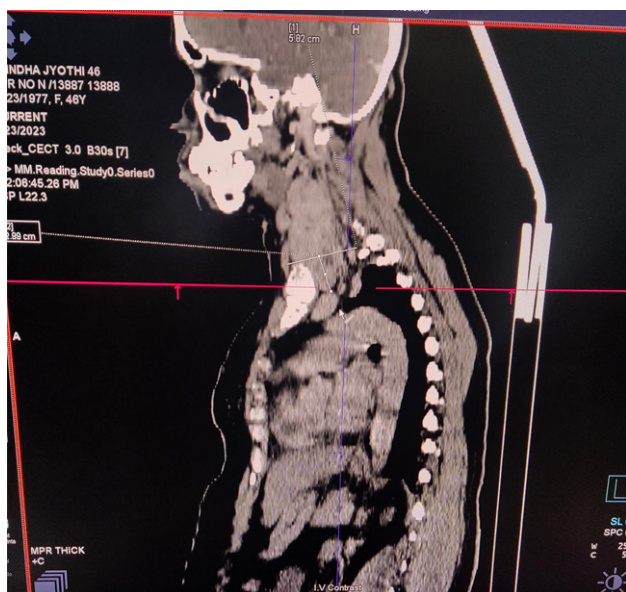


Figure 1. CT scan showing retrosternal thyroid

A comprehensive plan was developed preoperatively with a multidisciplinary team comprising Anesthesiologist, General surgeon and Cardiothoracic surgeon concentrating on the management of difficult airway and acute cardiorespiratory decompensation which could follow during induction of anesthesia.

A written high risk informed consent was obtained after explaining the complications related to difficult airway and hypoxia. A preoperative fasting of eight hours for solid food and two hours for clear fluid was instructed.

The patient was shifted to the operation theatre and multipara monitors including ECG, NIBP, pulse oximetry were attached. Premedication consisted of intravenous Glycopyrrolate 0.2mg as an antisialagogue, Xylometazoline nasal drops were instilled to facilitate the passage of fiberoptic bronchoscope without mucosal injury. The patient's airway was anesthetized by application of Lignocaine 2% jelly in the nostrils, Lignocaine viscous 2% gargles, 4ml of Lignocaine 4% nebulization with oxygen. Pharynx was sprayed with 10% Lignocaine spray to prepare the patient for fiberoptic intubation. Patient was administered 1mg Midazolam and 60 microgram Fentanyl intravenously to allay anxiety and for mild sedation.

Awake fiberoptic intubation was performed under Dexmedetomidine infusion titrated at 0.2 to 0.3 mcg/kg/h – A 6.5mm cuffed oral endotracheal tube (flexometallic) was introduced. One ml topical 2% Lignocaine was given in added doses via FOB channel using Spray-as-you-go technique, while advancing towards trachea to prevent reflexes. After crossing the vocal

cord 1ml aliquot of 2% lignocaine was given. On visualizing the carina, the endotracheal tube was introduced into the trachea by rail roading over the FOB and it was positioned above carina. FOB was removed.

Endotracheal tube position was reconfirmed by end tidal carbon dioxide and bilateral air entry: Endotracheal tube was secured using adhesive tapes. As there was no deterioration in hemodynamics or difficulty in ventilation, intravenous Propofol 50+40mg and intravenous Vecuronium 5mg bolus was given. Closed circuit was used to maintain anesthesia with Oxygen, Nitrous oxide, intermittent Isoflurane, Dexmedetomidine infusion and maintenance dose of Vecuronium. After completion of total thyroidectomy the patient was shifted to ICU for post op monitoring, gradual weaning and extubation. After 24 hours, a leak test was performed which was negative, patient was fully awake, conscious, oriented and hemodynamically stable. Patient was extubated after adequate gentle suction. Her recovery was uneventful without any respiratory compromise.

DISCUSSION

Retrosternal goiter is an enlarged thyroid gland which extends below the clavicle and sternum. It can cause compression and airway challenges in patients at any stage during anesthesia.³ Cardiovascular as well as respiratory complications can occur. Direct mechanical compression of the trachea or main bronchi or both by the retrosternal goitre may lead to total airway occlusion whereas external compression of major vessels like superior vena cava and pulmonary artery or even the heart may result in cardiovascular collapse which can be fatal.⁴

Position change is very important to relieve the mass effect of the retrosternal goitre and so the patient was induced on an operating table that enabled immediate changes in patient position.⁵ It is most important to identify the most comfortable position in terms of respiration and hemodynamics in symptomatic patients prior to surgery.⁶ The mass related compression is usually less in this position and hence decompensation may be corrected or minimized. A tiltable operating table helps in checking obstruction of the airways in relation to positioning changes through bronchoscope.⁷ Though patient cooperation is necessary, the advantage of awake FOI is that it offers low potential for airway loss.⁸

We had provided airway anesthesia through nebulized lignocaine since the presence of retrosternal mass prevented the administration of local injectable airway blocks. Discomfort during airway manipulation

is undesirable as it may lead to hemodynamic compromise in these patients. Administration of Dexmedetomidine infusion for conscious sedation was very helpful even though small hemodynamic perturbations could still occur. Dexmedetomidine is an alpha 2 adrenoreceptor agonist with sedative, anxiolytic and analgesic properties and most importantly devoid of respiratory depression. It has been shown to provide a smooth intubating condition during awake FOI.⁹ It gives a better patient tolerance than preservation of patient airways and hemodynamic stability. We maintained anesthesia with Oxygen, Nitrous oxide, intermittent Isoflurane and Dexmedetomidine.

CONCLUSION

Managing the airway in patients with massive retrosternal goitre presents a challenge, necessitating vital input from planning to execution. A multidisciplinary team, including anaesthesiologists, cardiothoracic surgeons and ENT specialists if required, is essential. Adequate preparation for multiple airway techniques is crucial. Fiberoptic bronchoscopy continues to be a valuable tool for addressing difficult airways in retrosternal goitres and should be integrated into the airway management plan.

END NOTE

Author Information

1. Dr. Hima Rajan, Post Graduate Trainee, Department of Anesthesiology, Government Medical College, Thrissur

2. Dr. Anju Mariam Jacob, Professor, Department of Anesthesiology, Government Medical College, Thrissur

Conflict of Interest: None declared

REFERENCES

1. Erdös G, Tzanova I. Perioperative anaesthetic management of mediastinal mass in adults. *European Journal of Anaesthesiology* | EJA. 2009 Aug 1;26(8):627-32.
2. Chao YK, Liu YH, Hsieh MJ, Wu YC, Liu HP, Wang CJ, et al. Controlling difficult airway by rigid bronchoscope--an old but effective method. *Interact Cardiovasc Thorac Surg*. 2005 Jun;4(3):175-9.
3. Kamath S, Naik S, Pratiksha N. Retrosternal Goitre-An Anaesthetic Challenge. *Journal of Clinical and Diagnostic Research*. 2019 Jan 1;13:01-3.
4. Olusomi BB, Aliyu SZ, Babajide AM, Sulaiman AO, Adegboyega OS, Gbenga HO, Adebisi RG. Goitre-related factors for predicting difficult intubation in patients scheduled for thyroidectomy in a resource-challenged health institution in North Central Nigeria. *Ethiopian journal of health sciences*. 2018 Mar 22;28(2):169-76.
5. Raval CB, Rahman SA. Difficult airway challenges-intubation and extubation matters in a case of large goiter with retrosternal extension. *Anesthesia Essays and Researches*. 2015 May 1;9(2):247-50.
6. El-Dawlatly A, Takrouri M, Elbakry A, Ashour M, Kattan K, Hajjar W, Obaid AA. Perioperative management of huge goiter with compromised airway. *Internet J Anesthesiol*. 2002;7(2).
7. Cook TM, Morgan PJ, Hersch PE. Equal and opposite expert opinion. Airway obstruction caused by a retrosternal thyroid mass: management and prospective international expert opinion. *Anaesthesia*. 2011 Sep;66(9):828-36.
8. Sajid B, Rekha K. Airway management in patients with tracheal compression undergoing thyroidectomy: A retrospective analysis. *Anesthesia Essays and Researches*. 2017 Jan 1;11(1):110-6.
9. Klingler K, Infosino A. Airway Management. In: Jr Pardo MC, Miller RD (Ed.). *Basics of Anaesthesia*, 7th ed. Philadelphia. Elsevier. 2018.p.256-58.