

Randomised Controlled Trial of Mitomycin-C Versus Standard Care in Middle Meatal Antrostomy

Shaheer Ibrahim A^a, Krishnan K^a, Rajamma KB^a

a. Department of ENT, Sree Gokulam Medical College & Research Foundation, Trivandrum, Kerala, India*

ABSTRACT

Published on 21st December 2020

Background: Perioperative use of topical Mitomycin-C has been found to be effective in reducing stenosis and synechiae formation after Endoscopic Sinus Surgery (ESS). Meticulous postoperative care with frequent nasal douching can prevent crusting and adhesion to a great extent. This study is to examine the clinical effects of Mitomycin-C applied to the sinonasal mucosa and to determine whether such an application significantly alters the incidence of postoperative maxillary sinus ostium stenosis and adhesion formation thereby improving the surgical outcome.

Materials & Methods: Randomised controlled trial of Mitomycin-C versus standard care in Middle meatal antrostomy in prevention of post operative synechiae and ostial stenosis. This study was conducted in a tertiary care teaching hospital in Kerala state of India, from December 2012 to May 2014. A total of 60 patients were included in this, consists of 30 experimental group and 30 control group. Intra operatively Mitomycin-C (MMC) was topically applied over the Middle meatal antrostomy site in the experimental group.

Results: There was a statistically significant difference in the occurrence of maxillary sinus ostium stenosis and synechiae formation in the experimental group with Mitomycin-C application as compared to the control group in the 1st, 3rd and 6th month follow up. At 3 months 40% in control group got synechiae, and only 3.3% in experimental group (p-value = 0.001), and in 6 months 56.7% of the control group got synechiae compared with 6.7% in experimental group (p-value = <0.0001) A highly significant reduction in stenosis, compared to control group after six months of surgery in experimental group (93.3 % experimental group were free from stenosis compared to 66.7% of the control group, p-value of 0.009.

Conclusion: The topical application of MMC is helpful in prevention of post operative complications like synechiae formation and ostial stenosis.

Keywords: Middle Meatal Antrostomy, Mitomycin-C, Synechiae Formation, Ostial Stenosis

*See End Note for complete author details

INTRODUCTION

Chronic Rhinosinusitis (CRS) is one of the most common causes for an individual seeking medical care. Rhinosinusitis is a group of disorders characterized by inflammation of the mucosa of nose and para nasal sinuses. The diagnosis of CRS is based on Rhinosinusitis Task Force criteria (Accepted by American Academy of Otolaryngology).¹ According to that the symptoms should last for a minimum duration of 12 consecutive weeks. The main symptoms included are nasal obstruction, nasal discharge, headache, loss of smell, facial pain, sneezing, and post nasal discharge.²

After eliciting proper history, all the patients should undergo anterior rhinoscopic examination, followed by Diagnostic Nasal Endoscopy (DNE). Nasal endoscopy improved the diagnostic accuracy of CRS with polyp

formation due to high quality magnified view.³ The medical management of CRS focuses on relieving the mucosal edema and obstruction of the sinus ostia, there by re-establishing sinus ventilation and drainage. Failure of medical therapy, after giving broad spectrum or culture sensitive antibiotics and other adjunct supportive medications for 3 months is an indication for endoscopic sinus surgery.⁴

Functional Endoscopic Sinus Surgery (FESS) is a surgical procedure for removing diseased tissue from nasal cavity and paranasal sinuses and it restores the mucociliary clearance. It has become a well-established surgical procedure in the management of CRS. All the patients who do not improve with medical management should undergo CT scan Nose and Paranasal sinuses to confirm the diagnosis, stage the extent of disease and evaluate the anatomy for the surgical in-

Cite this article as: A SI, Krishnan K, Rajamma KB. Randomised Controlled Trial of Mitomycin-C Versus Standard Care in Middle Meatal Antrostomy. IMA Kerala Medical Journal. 2020 Dec 21;13(4):135-40.

Corresponding Author:

Dr Shaheer Ibrahim A, Resident, Department of ENT, Sree Gokulam Medical College & Research Foundation, Trivandrum, Kerala, India. E-mail: shaheernowonline@gmail.com

tervention.⁵ Surgery is almost always indicated in nasal polyp because the medical therapy helps only to reduce the size but does not eliminate the polyp.

Postoperative maxillary sinus ostium stenosis and synechia formation are the major causes of failure after the Endoscopic Sinus Surgery (ESS).⁶ So the patency, the anrostomy size and the absence of adhesion formation in the middle meatus are the significant factors in the evaluation of a successful ESS. Adhesion and stenosis after ESS are usually due to scar or granulation tissue formation during the tissue recovery process. Meticulous postoperative care with frequent nasal douching can prevent crusting and adhesion to a great extent. Perioperative use of topical Mitomycin-C has been found to be effective in reducing stenosis and synechia formation after ESS.⁷

Mitomycin-C is an antibiotic isolated from the broth of streptomyces caespitosus. It acts as an alkylating agent with the ability to inhibit DNA synthesis.⁸ It has also been shown to inhibit fibroblast proliferation which reduces the scar tissue formation. Studies about MMC on cultured fibroblasts shows antiproliferative effect at concentrations of .04 mg/ml. The purpose of this study is to examine the clinical effects of Mitomycin-C applied to the sinonasal mucosa and to determine whether such an application significantly alters the incidence of postoperative maxillary sinus ostium stenosis and adhesion formation thereby improving the surgical outcome.

MATERIALS AND METHODS

A Randomized Control Trial (RCT) conducted in the department of ENT of a tertiary hospital in Kerala state of India. The study period was from December, 2012 to May, 2014. Patients with chronic rhinosinusitis, with and without polyp in the age group 18-60 years which includes both males and females, who have undergone Functional Endoscopic Sinus Surgery were included in the study. A total of 60 were taken as sample size, which constitutes of 30 experimental group and 30 controls. The sample size was calculated using power and sample size programme, with an alpha error of 5% and a power of 80%.

Thirty patients were selected and in each patient bilateral Middle meatal anrostomy (MMA) was done. The experimental medicine (Mitomycin-C) was applied randomly on one MMA site in each patient and standard care (Normal saline) was applied to the other MMA side. The Mitomycin-C applied area is taken as experimental group and the other side as control group.

Experimental group and control group were decided by simple randomization technique. This was done to eliminate the confounding factors. CRS has an immunological etiology and the nature of tissue response to trauma is different in different individuals, these two factors can be matched by selecting case and control groups in the same individual.

Adult patients aged above 18 yrs, who have symptoms, signs, Nasal endoscopy findings and CT findings were suggestive of Bilateral Chronic Rhinosinusitis with or without polyp refractory to Medical treatment and underwent FESS were taken as inclusion criteria. Patients with gross nasal deformities like Deviated Nasal septum, grossly hypertrophied turbinate, local diseases like invasive fungal sinusitis, suspected malignancy, unilateral rhinosinusitis, past history of nasal surgery, uncontrolled hypertension, diabetes or any other systemic illness, and patients unwilling or unable to comply with regular post-operative visits were excluded from the study.

Each of the participants was explained regarding the study and informed written consent was taken from all the patients for the planned procedure in proforma approved by our institutional ethical committee. They were also informed about the topical use of Mitomycin-C. Detailed history was taken followed by careful clinical examination, routine hematological tests then diagnosis was confirmed by Nasal Endoscopy and Non contrast Computerized Tomogram Scan of Nose & PNS with 2-5mm coronal and axial cuts.

All the patients were operated under general anesthesia. The amount and location of sinus disease present determined the extent of sinus surgery performed for each patient. Bilateral Middle meatal anrostomy, anterior ethmoidectomy and posterior ethmoidectomy were done in all patients. Polyps were removed and specimen sent for histopathological examination. In all cases the maxillary ostia were widened at least 1.5 cm and it was measured with a measuring probe bilaterally. At the completion of the procedure, cotton pledgets saturated with 0.8 mg/ml of MMC was applied locally over the test MMA site whereas saline soaked cotton pledgets applied over the control site. After a period of 5 minutes, the cotton pledgets were removed and nasal cavity was irrigated. The measuring probe is used to measure the Middle meatal anrostomy size. Post operatively middle meatal anrostomy site is assessed and all the parameters were noted. All patients were made to undergo follow up nasal endoscopies at the end of one week, one month, third month, and sixth month. The patency of maxillary ostium and adhesion were assessed and compared between control and test site.

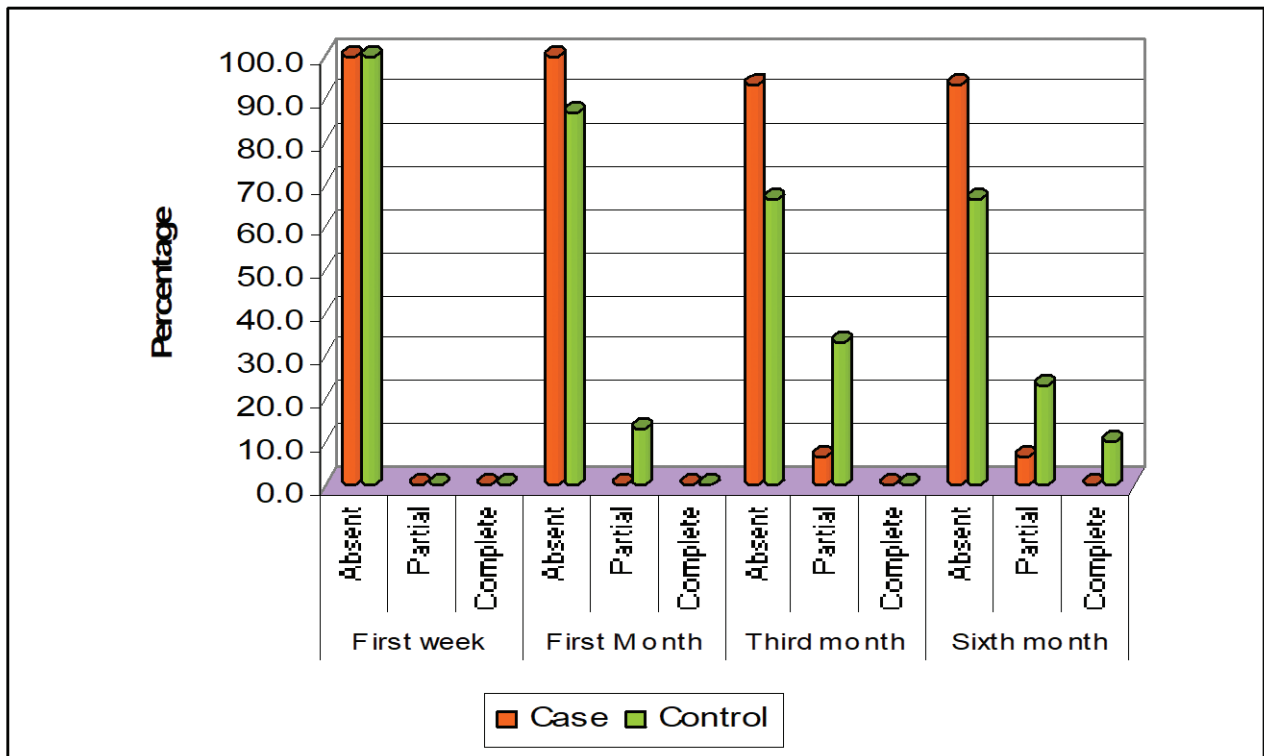


Figure 1. Comparison of stenosis at different intervals of time

Patients were scored according to the postoperative endoscopic staging system in which parameters assessed were as follows (each carrying a minimum score of 0 and a maximum score of 2). Maxillary ostium stenosis was measured in terms of; absent (score -0), partial (score-1), and complete (score-2), and the Synechia/ Adhesion; absent (Score-0), partial (score -1), complete (score-2).

Statistical analysis of the study parameters was done using the Mann-whitney U test. A ‘p’ value of less than 0.05 was considered significant..

RESULTS

During the study period, 30 patients with bilateral Chronic Rhinosinusitis with or without nasal polyp were recruited for the study. All patients were received bilateral Middle meatal antrostomy. Each patient got an experimental side and control side, which was selected randomly. Mitomycin-C was applied to experimental side (experimental group) and standard normal saline was applied to control side (control group) after completion of the Endoscopic Sinus Surgery.

There were no stenosis found in both control and experiment group in first week of postoperative period (Figure 1).

A significant reduction in Maxillary Ostium Stenosis was obtained in experimental group, when compared with control group after one month of post operative period. 1st month, 100% of the experimental group was free from stenosis compared to 86.7% in control group, which was found to be significant with a p-value of 0.04 (Table 1).

It was found to that a highly significant reduction in stenosis, compared to control group after six months

Table 1. Post-operative Maxillary Ostium Stenosis

Duration of post-operative period	Maxillary Ostium Stenosis	Experimental group		Control group		p-value
		Count	Percent	Count	Percent	
First week	Absent	30	100.0	30	100.0	1.000
	Partial	0	0.0	0	0.0	
	Complete	0	0.0	0	0.0	
First Month	Absent	30	100.0	26	86.7	0.040
	Partial	0	0.0	4	13.3	
	Complete	0	0.0	0	0.0	
Third month	Absent	28	93.3	20	66.7	0.010
	Partial	2	6.7	10	33.3	
	Complete	0	0.0	0	0.0	
Sixth month	Absent	28	93.3	20	66.7	0.009
	Partial	2	6.7	7	23.3	
	Complete	0	0.0	3	10.0	

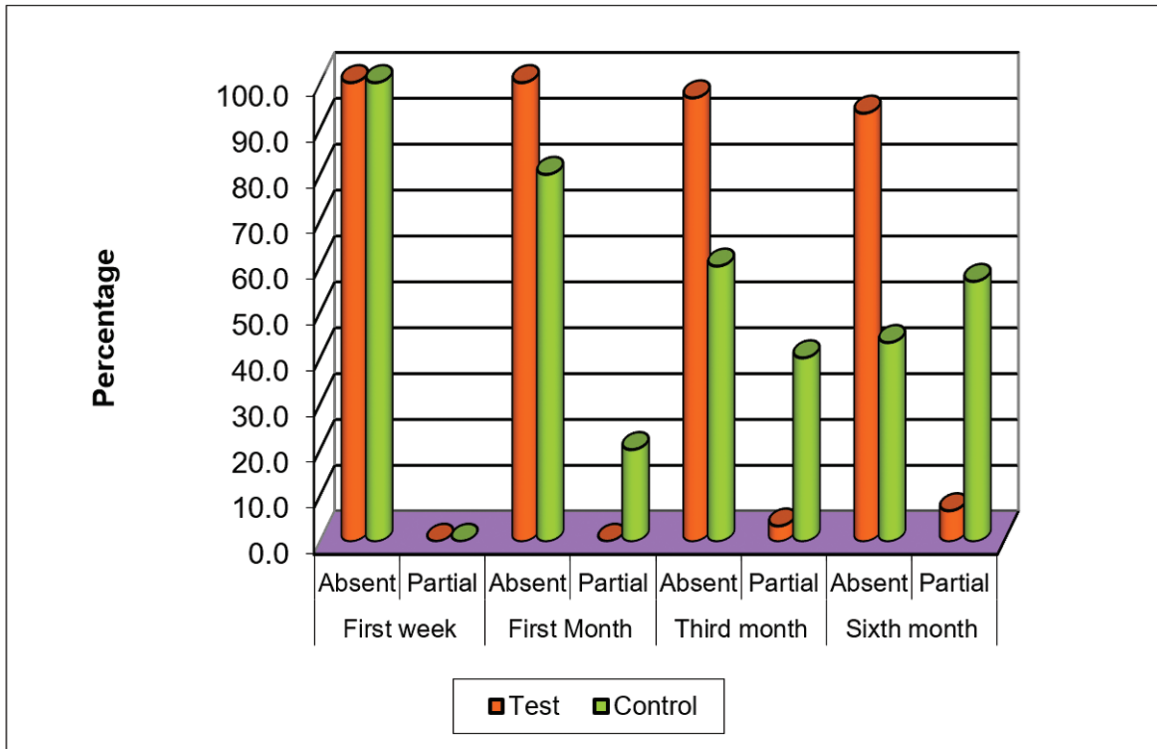


Figure 2. Post-operative Synechia/ Adhesion formation

of surgery in experimental group (93.3 % experimental group were free from stenosis compared to 66.7% of the control group, p-value of 0.009.

Post-operative synechia/Adhesion formation were absent in both experimental and control group in first week of post-operative period (Figure 2). Post-operative synechia/Adhesion formation were less in experimental group compared to control group in first month of post-operative period with 20% partial synechia in control group compared with no synechia in experimental group, which was found to be significant, p-value of 0.01. In third month and sixth month, there was a significant reduction in post-operative period also there was a highly significant reduction in synechia in experimental group compared with control group. At 3 months 40% in control group got synechia, and only 3.3% in experimental group (p-value = 0.001), and in 6 months 56.7% of the control group got synechia compared with 6.7% in experimental(MMC) group (p-value = <0.0001) (Table 2).

DISCUSSION

Sinusitis is one of the most common healthcare problems worldwide and its incidence and prevalence are increasing day by day. In India the true prevalence and incidence is unknown, because a large proportion of patients do not seek medical care. Endoscopic Sinus Surgery is now the main stay of surgical treatment

in chronic rhinosinusitis. Normal mucosal preservation and minimal anatomical distortion during ESS gives better results. Techniques developed by Messer Klinger mainly rely upon limited surgical procedures and minimal manipulation of all the major sinuses.⁹

Unfortunately, there is significant number of patients with persistent sinus symptoms after one or more sinus surgeries. Recurrent mucosal disease and persistent anatomical obstruction are the most common reasons for failure of operation. Anatomical obstruction is mostly due to maxillary ostial stenosis and adhesion formation. Ramadan et al noted that 56% of patients undergoing revision ESS had adhesions, 27% of patients had maxillary ostium stenosis.¹⁰ This fact emphasizes that the surgeon’s skill is not the most important factor deciding the occurrence of adhesion formation but the

Table 2. Post operative Synechia/ Adhesion formation

Post-operative period	Synechia	Experimental		Control		P-value
		Count	Percent	Count	Percent	
First week	Absent	30	100.0	30	100.0	1.000
	Partial	0	0.0	0	0.0	
First Month	Absent	30	100.0	24	80.0	0.010
	Partial	0	0.0	6	20.0	
Third month	Absent	29	96.7	18	60.0	0.001
	Partial	1	3.3	12	40.0	
Sixth month	Absent	28	93.3	13	43.3	0.0001
	Partial	2	6.7	17	56.7	

Table 3. Comparison of maxillary sinus ostium stenosis with other studies

Study	Maxillary osteum stenosis	
	Test side (MMC)	Control side
Present study	6.7 %	33.3 %
Konstantinidis et al	6.6 %	29.7 %
Tilakraj singh et al	3.3 %	33.3 %

patient factors, local and post-operative management measures also influence the same.

The amount of raw area created following surgery and the person's innate fibroblastic activities plays an important role in scar tissue formation after ESS. Post operatively, raw areas lying in close proximity heals by fibrous tissue proliferation. This leads to adhesion formation between middle turbinate and lateral nasal wall. Maxillary sinus drainage is impaired due to adhesion formation and maxillary ostial stenosis. Fibroblastic proliferation is reduced by intra operative topical application of Mitomycin-C.¹¹

Various techniques were described to prevent the adhesion formation in the nasal cavity, which account for the majority of failures after ESS. Middle turbinate medialisation techniques were described to reduce this adhesion.¹² But the risk of olfactory compromise has not been proven by the studies. Middle meatal packing is an alternative method to prevent adhesions. A variety of nasal packing materials were described, although a recent study found that no one material is better than the other in preventing adhesion.¹³ A different method by using nasal splint showed significant post-operative discomfort in most of the patients. Malki D showed that various morbidities were associated with nasal splints, which in turn disqualified their routine use after ESS.¹⁴

Other methods include middle meatal spacers or nasal packing to prevent adhesions. Friedman et al have used a Telfa pack for 24-48 hrs after ESS. Floseal when used for nasal packing after ESS was shown to minimize bleeding and synechia formation. Middle meatal antrostomy stents were described to prevent stenosis and to improve post-operative outcome. Even after using all the above measures the rate of adhesion formation was found to range from 11% to 35%. More over some of these measures add considerable morbidity requiring prolonged care and increased cost of treatment.

A single 5 minute topical application of MMC has a measurable effect on cell proliferation and cellular morphology for up to 36 hrs.¹⁵ The effect of MMC as

Table 4. Comparison of synechia formation with other studies

Study	Adhesion / Synechia	
	Test side (MMC)	Control side
Present study	6.7 %	56.7 %
Konstantinidis et al	6.6 %	15.6 %
Tilakraj singh et al	6.7 %	33.3 %
Venkatraman et al	13.3 %	86.6 %

a topical agent is well established in ophthalmology in the treatment of pterygium and glaucoma surgeries.¹⁶ In otolaryngology MMC is used to prevent post-operative scarring by preventing collagen deposition and fibroblast proliferation. In rhinology the main use of MMC is to prevent adhesion formation.

Earlier in animal studies by Ingrams et al found out that antrostomies in the control group and .04mg/ml treatment groups tended to close by one week post operatively, but treatment groups with .4mg/ml remained patent for four weeks and in 1.0 mg/ml groups ostium was patent for 12 weeks.

A study by Musy and Kountakis found that 39% of patients with ostiomeatal block had middle meatal antrostomy stenosis. In the present study there was a statistically significant difference in the occurrence of maxillary sinus ostium stenosis in test group with MMC application as compared to the control group in the 3rd and 6th month follow up. Similar results were also seen in a study conducted by Konstantinidis L et al and Tilakraj singh et al (**Table 3**).

The location and size of adhesion has an impact on the obstruction of sinus ostium and further development of sinus infections. In the present study, incidence of adhesion is less in the test side where the MMC was applied as compared to the control group and the difference is statistically significant. The study shows the effect of MMC in reduction of synechia/adhesion formation. Similar results were seen in the previous studies conducted by Konstantinidis et al, Tilakraj singh et al and venkatraman et al (**Table 4**).

CONCLUSION

This study showed a significant reduction in the incidence of maxillary sinus ostium stenosis and synechia formation in patients with topical application of Mitomycin-C. It indicates the efficacy of topically applied Mitomycin-C in reducing the post-operative complications of Endoscopic Sinus Surgery, thereby improving surgical outcomes in patients with chronic rhinosinusitis with or without polyp.

END NOTE

Author Information

1. Dr Shaheer Ibrahim A, Resident
Department of ENT, Sree Gokulam
Medical College & Research Foundation,
Trivandrum, Kerala, India.
2. Krishnan K, Assistant Professor, Department of
ENT, Sree Gokulam Medical College & Research
Foundation, Trivandrum, Kerala, India
3. Rajamma KB, Professor & HOD, Department of
ENT, Sree Gokulam Medical College & Research
Foundation, Trivandrum, Kerala, India

Conflict of Interest: None declared

REFERENCES

1. Lanza DC, Kennedy DW: Adult rhinosinusitis defined. *Otolaryngol Head Neck Surg* 1997; 117:S1-S7.
2. Benninger MS, Ferguson BJ, Hadley JA, et al: Adult chronic rhinosinusitis: Definitions, diagnosis, epidemiology, and pathophysiology. *Otolaryngol Head Neck Surg* 2003; 129:S1-S32.
3. Benninger MS. Nasal endoscopy: Its role in office diagnosis. *American Journal of Rhinology*. 1997; 11: 177-80.
4. Bachert C, Hormann K, Mosges R, et al. An update on the diagnosis and treatment of sinusitis and nasal polyposis. *Allergy* 2003; 58: 176-191.
5. Krouse J: CT stage, allergy testing and quality of life in patients with sinusitis. *Otolaryngol Head Neck Surg* 2000; 123:389-391
6. Ramadan HH. Surgical causes of failure in endoscopic sinus surgery. *Laryngoscope* 1999;109:27-29.
7. Konstantinidis I, Tsakiropoulou E, Vital I, Triaridis S. Intra And Post-operative application of Mitomycin-C in the middle meatus reduces adhesions and antrostomy stenosis after FESS. *Rhinology*. 2008 Sep;46(3):249.
8. Danshiitsoodol N, De pinho CA, Matoba Y, Kumaga T, Sugiyama M. The Mitomycin-C binding protein from Mitomycin producing micro organisms protects from the lethal effect of bleomycin. *Crystallographic analysis of elucidate binding mode of the antibiotic to the protein*. *J molec biol*. 2006;360(2):398-408.
9. Stammberger H: Endoscopic endonasal surgery—concepts in treatment of recurring rhinosinusitis: Part I. Anatomic and pathophysiological considerations. *Otolaryngol Head Neck Surg* 1986; 94:143-147.
10. Ramadan HH. Surgical causes of failure in endoscopic sinus surgery. *Laryngoscope* 1999;109:27-29.
11. Danshiitsoodol N, De pinho CA, Matoba Y, Kumaga T, Sugiyama M. The Mitomycin-C binding protein from Mitomycin producing micro organisms protects from the lethal effect of bleomycin. *Crystallographic analysis of elucidate binding mode of the antibiotic to the protein*. *J molec biol*. 2006;360(2):398-408.
12. Hewitt KM, Orlandi RR. Suture medialization of the middle turbinates during endoscopic sinus surgery. *Ear Nose Throat J*. 2008 Dec;87(12):E11.
13. Franklin J H, Wright E D. Randomized, controlled, study of absorbable nasal packing on outcomes of surgical treatment of rhinosinusitis with polyposis. *American journal of Rhinology* . 21[2]; 214-217.
14. Dijkstra M D et al. Fluticasone propionate aqueous nasal spray does not influence the recurrence rate of chronic rhinosinusitis and nasal polyps 1 year after FESS. *Clin Exp. Allergy* . 34: 1395-1400.
15. Sanclement JA, Webster P, Thomas J, et al: Bacterial biofilms in surgical specimens of patients with chronic rhinosinusitis. *Laryngoscope* 2005; 115:578-582.
16. Lal J, Stankiewicz J.A. Primary Sinus Surgery. In: Lund.V.J, editor. *Cummings Otolaryngology Head and Neck Surgery*. Fifth ed. 2010; 2158-2171.