

Bilateral Traumatic Dislocation of Testes: Case Report

Arun B^a, Dhanya MR^b, Gini AK^a

a. Department of General surgery, Sree Gokulam Medical College & Research Foundation, Kerala, India;

b. Department of Anaesthesiology, Sree Gokulam Medical College & Research Foundation*

ABSTRACT

Published on 23rd March 2020

Traumatic dislocation of testis is a rare occurrence and usually occurs following a motorcycle collision, in what is referred to as “fuel tank injury”. Early identification and subsequent surgical management is of utmost importance to maintain normal spermatogenesis in the dislocated testis. In appropriate clinical setting, scrotal ultrasound examination with gray-scale and color flow Doppler imaging is the method of choice for diagnosis. Computed tomography of the abdomen is a useful adjunct procedure. We report bilateral traumatic testicular dislocation in a young man, which was successfully treated by open exploration and Orchiopexy.

Keywords: Ectopic Testis, Fuel Tank Injury, Traumatic Dislocation of Testis

*See End Note for complete author details

INTRODUCTION

Testicular dislocation is a rare complication of testicular trauma and is defined as displacement of one or both normally located testes out of the scrotum.¹ Traumatic dislocation of testis is an extremely rare occurrence following high velocity motorcycle accidents and bilateral dislocation is rarer still. Traumatic testicular dislocation occurs by the mechanism of direct pressure exerted on the scrotum.² Motorcycle collisions are the most frequent causative mechanism, usually related to deceleration straddle injuries.² Though it was first reported by Claubry in 1818, only about 120 cases have been documented in literature ever since. We report bilateral traumatic testicular dislocation in

a young man, which was successfully treated by open exploration and Orchiopexy.

CASE REPORT

An eighteen year old boy presented to the Urology outpatient department with absent testes in both the scrotum since a road traffic accident, he had suffered one month back. He had a high velocity motorcycle accident following which he had sustained fractures involving femur, radius, superior and inferior pubic rami. He was sure that both the testis was within the scrotum prior to the accident. Surgical correction of the fractures was done within two days of the accident.

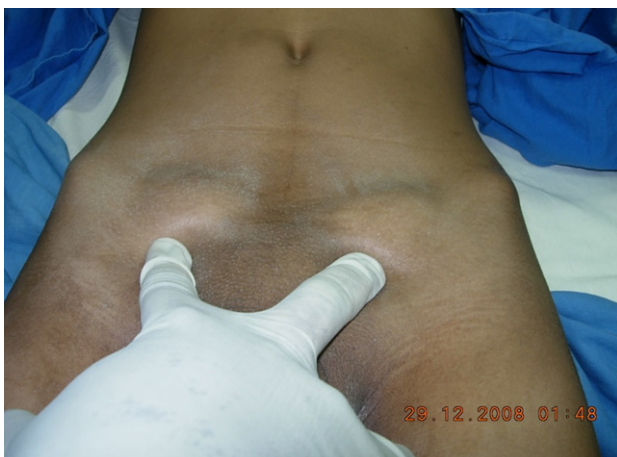

Figure 1. Bilaterally dislocated testes



Figure 2. Bilateral empty well developed scrotum

Cite this article as: Arun B, Dhanya M, Gini AK. Bilateral Traumatic Dislocation of Testes: Case Report. IMA Kerala Medical Journal. 2020 Mar 23;13(1):17–20.

Corresponding Author:

Dr Arun B, Associate Professor, Department of General surgery, Sree Gokulam Medical College & Research Foundation, Kerala, India. E-mail: arunbdr@gmail.com

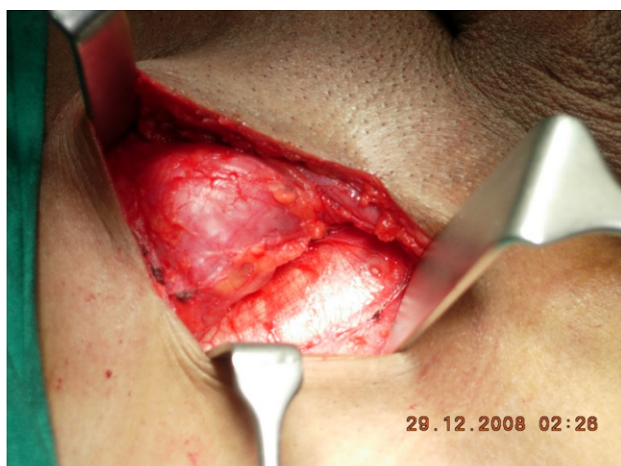

Figure 3. Testis seen in superficial inguinal pouch

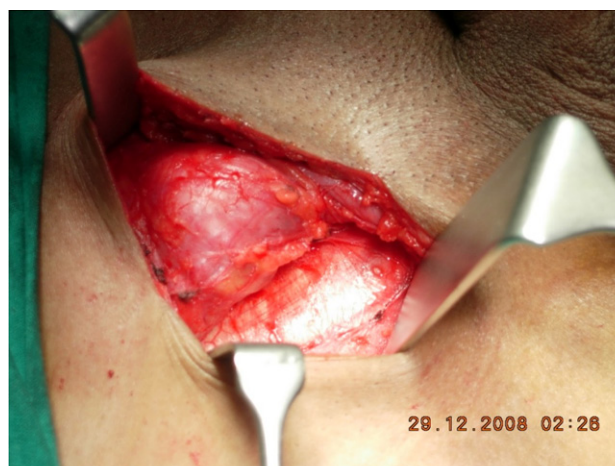

Figure 4. Testis being released

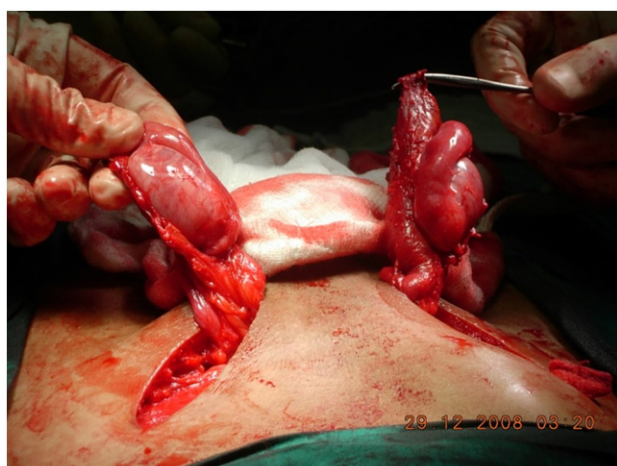

Figure 5. Both testes released

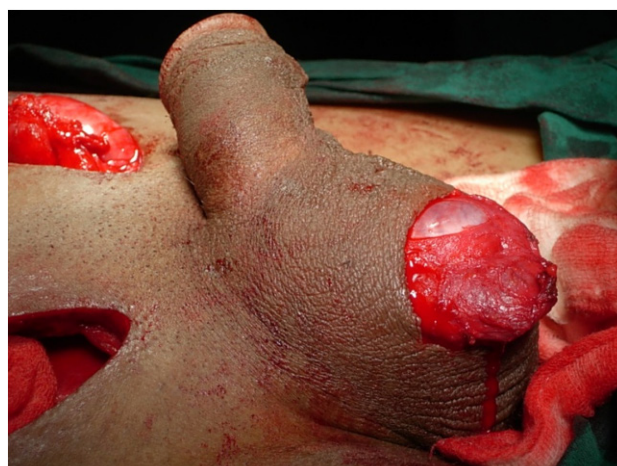

Figure 6. Testis being placed in subdartos pouch

Examination revealed two oval masses on either side in the inguinal region which were soft, immobile and tender. Scrotum was well developed on both sides and empty. Doppler USG showed that both the testicles were located subcutaneously in the inguinal region and were of normal size and vascularity.

Closed reduction of the testes to its rightful position was attempted under general anesthesia but failed. Hence bilateral inguinal exploration was done. Both testes were found to be dislocated into a plane superficial to external oblique aponeurosis and they were extensively adherent. Both the testes were released from surrounding tissues. Bilateral subdartos pouch were created and orchiopexy was done.

DISCUSSION

Traumatic dislocation of testis is a rare condition which usually follows high velocity road traffic accidents, especially motorcycle accidents.³ Patients usually present with a painful palpable mass either in the inguinal

region, prepubic area, or crural location.⁴ On account of the sudden deceleration the rider is propelled forward causing the perineum and scrotum to be struck in the midline by the fuel tank. The shape of the tank is such that it drives a smooth wedge into the groin thereby forcibly displacing testes in a lateral and superior direction. On reaching the external ring the testis may be pushed into the inguinal canal and may proceed as far as retroperitoneum or more commonly it is displaced into the superficial inguinal pouch. Superficial inguinal pouch is the commonest reported location for a dislocated testis and occurs in 40-50% of the cases.⁵ Very often, testicular dislocation goes unnoticed as associated polytrauma often precludes early detection. Most dislocations occur immediately after trauma, although some may develop days or even weeks later. The dislocation of the testis is commonly unilateral but can be bilateral as seen in about 30% of the cases.^{6,4}

Testicular dislocation can be categorized into two types.⁵ In Type 1 (Internal dislocation), the testis

Sites	Percentage
Superficial Inguinal	50%
Pubic	18%
Canalicular	8%
Penile	8%
Abdominal	6%
Acetabular	4%
Perineal	4%

is displaced to the inguinal canal or the abdominal cavity through the external /internal inguinal ring. In Type 2 (Superficial dislocation), the dislocated testis is located superficially in the subcutaneous regions such as the inguinal, pubic, crural, penile, or acetabular regions.³ A “Compound dislocation” of the testis is a special category in which traumatic extrusion of the testis occurs through the skin of the scrotum. It is an extremely rare occurrence, first described by Alyea in 1929.⁷

In appropriate clinical setting, scrotal ultrasound examination with gray-scale and color flow Doppler imaging is the method of choice for diagnosis.⁸ USG or CT scan may be done to demonstrate capsular or parenchymal damage of testis or any evidence of torsion. In case of testicular dislocation, the testis should be brought back into the scrotum to decrease the risk of trauma, torsion or impaired spermatogenesis.

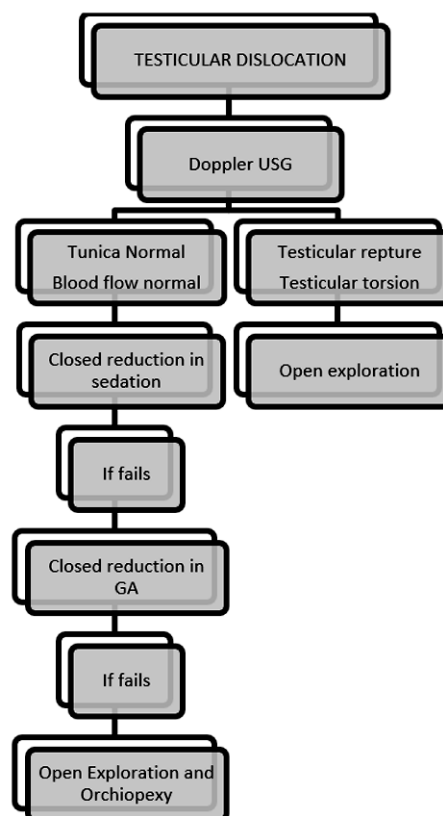
Predisposing factors for testicular dislocation includes, young age (cremasteric reflex strong), lax external ring, atrophic testis and associated indirect hernia.

Early diagnosis and treatment are necessary to prevent complications. In rare situations, the dislocated testis can descend spontaneously⁸ Manual reduction is reported to be successful in only 15% of the cases because of the small size defect in the spermatic cord layers and the edema following trauma. Surgical interventions include groin exploration, open reduction, and orchidopexy to prevent any possible future torsion.⁹

CONCLUSION

Traumatic dislocation of testis is an extremely rare occurrence following high velocity motorcycle accidents and bilateral dislocation is rarer still. Absence of the testis in the scrotal sac should raise a suspicion of a dislocated testis, and an attempt should be made to locate the dislocated testis by ultrasound examination. USG or CT scan may be done to demonstrate capsular or parenchymal damage of testis or any evidence of torsion. Early surgical management with reduction and orchidopexy is essential to reposition the testis and preserve the spermatogenesis.

Management Algorithm



opexy is essential to reposition the testis and preserve the spermatogenesis.

END NOTE

Author Information

1. Dr Arun B, Associate Professor, Department of General surgery, Sree Gokulam Medical College & Research Foundation, Kerala, India
2. Dr Dhanya M, Assistant Professor, Department of Anaesthesiology, Sree Gokulam Medical College & Research Foundation
3. Dr Gini AK, Associate Professor, Department of General surgery, Sree Gokulam Medical College & Research Foundation, Kerala, India

Conflict of Interest: None declared

REFERENCES

1. Sakamoto H, Iwasaki S, Kushima M, Shichijo T, Ogawa Y. Traumatic bilateral testicular dislocation: a recovery of spermatogenesis by orchidopexy 15 years after the onset. Fertil Steril. 2008 Nov;90(5):2009.e9–11.
2. Smith CS, Rosenbaum CS, Harris AM. Traumatic bilateral testicular dislocation associated with an anterior posterior compression fracture of the pelvis: a case report. J Surg Orthop Adv. 2012;21(3):162–4.
3. Ihama Y, Fuke C, Miyazaki T. A two-rider motorcycle accident in-

- volving injuries around groin area in both the driver and the passenger. *Leg Med Tokyo Jpn.* 2007 Sep;9(5):274–7.
4. Kilian CA, Paz DA, Patel SA, Austin MJ, Richman KM, Pretorius DH. False diagnosis of ruptured testes in a case of traumatic dislocation. *J Ultrasound Med Off J Am Inst Ultrasound Med.* 2009 Apr;28(4):549–53.
 5. Bromberg W, Wong C, Kurek S, Salim A. Traumatic bilateral testicular dislocation. *J Trauma.* 2003 May;54(5):1009–11.
 6. Schwartz SL, Faerber GJ. Dislocation of the testis as a delayed presentation of scrotal trauma. *Urology.* 1994 May;43(5):743–5.
 7. Alyea EP. Dislocation of testis. *Surg Gynecol Obstet.* 1929;(49:600).
 8. Perera E, Bhatt S, Dogra VS. Traumatic ectopic dislocation of testis. *J Clin Imaging Sci.* 2011;1:17.
 9. Blake SM, Bowley DM. Traumatic dislocation of the testis: a rare sequel of perineal injury. *Emerg Med J EMJ.* 2003 Nov;20(6):567.