

# Posterior Reversible Encephalopathy Syndrome (PRES): A Rare Complication with Gestational Hypertension and Preeclampsia

Bindu Thampi<sup>a</sup>, Manjusha Viswanathan<sup>b</sup>, Suja Daniel<sup>b</sup>, Manoj P<sup>c</sup>

a. Department of Ophthalmology, Sree Gokulam Medical College & Research Foundation, Venjaramoodu;

b. Department of Obstetrics and Gynecology, Sree Gokulam Medical College & Research Foundation, Venjaramoodu;

c. Department of Medicine, Sree Gokulam Medical College & Research Foundation, Venjaramoodu\*

## ABSTRACT

Published on 24<sup>th</sup> June 2019

Incidence of pre eclampsia is 6-8% of all pregnancies worldwide. Two major complications of pre eclampsia include eclampsia and HELLP syndrome. In United Kingdom, eclampsia occurs in 1 in 2000 deliveries and has a mortality of 1.8%. HELLP syndrome occurs in 1 in 500 deliveries and can be as dangerous as eclampsia. In India the incidence of eclampsia is 3-4% with maternal mortality ratio of 10.44% and incidence of HELLP syndrome is 10-12% with a maternal mortality of 18%. In very rare cases, temporary vision loss can occur due to partial or complete cortical blindness due to petechial hemorrhages and focal vasogenic edema in the occipital cortex. The reported incidence of posterior reversible encephalopathy syndrome (PRES) is 0.01%. We are reporting a case of PRES that was a cause of total cortical blindness in a patient with preeclampsia which was completely reversed with timely intervention and supportive treatment.

**Keywords:** PRES, Posterior Reversible Encephalopathy Syndrome, Eclampsia, Cortical Blindness

\*See End Note for complete author details

## BACKGROUND

Posterior reversible leukoencephalopathy syndrome is a rare complication with gestational hypertension and preeclampsia. First reported case of reversible cortical blindness was in 1996 by Hinchey et al.<sup>1</sup> In the year 2000 this condition was called posterior reversible encephalopathy syndrome (PRES). It is also called reversible posterior leukoencephalopathy syndrome (RPLS). Before 1996 there were several case reports describing the CT and MRI findings similar to that of PRES as an interesting finding of eclampsia.<sup>2</sup> This is a very rare complication of pre-eclampsia with an incidence of 0.01%.<sup>3</sup> A few cases has been reported in the literature by Maggi et al, Singhal et al and others related to pregnancy. In all these cases the PRES was preceded by severe hypertension, headache (thunderclap) and convulsions. In our case only THUNDER CLAP headache was present followed by complete loss of vision which is an alarming complication in the post natal period. It is a self limiting condition when blood pressure is controlled. Prompt control of blood pressure is warranted to prevent

further cortical damage and neurological deficit.<sup>4,5</sup>

## CASE REPORT

A 32 year old gravida three with one live child and one abortion was detected to have gestational hypertension at 35 weeks of gestation with a blood pressure (BP) of 140/100mmHg. She was on regular antenatal checkups from our department. Physical examination was unremarkable and her routine investigations, renal and liver function test were within normal limits. She was started on antihypertensive alpha methyl dopa at 250 mg thrice daily and her blood pressure was maintained at 130/90 mm of Hg. Elective LSCS was done at 37 completed weeks of pregnancy as she had a previous LSCS due to contracted pelvis. Pre-operative and intra-operative blood pressures were well controlled. Immediate post-operative period was uneventful. As her blood pressure was normal post-operatively anti-hypertensives were withheld. On post-operative day 4, BP was found to be 170/120mm Hg. Antihypertensive atenolol 25 mg daily was started. On post operative day 6, she developed sleeplessness, headache and sudden loss

*Cite this article as:* Thampi B, Viswanathan M, Daniel S, Manoj P. Posterior Reversible Encephalopathy Syndrome (PRES): A Rare Complication with Gestational Hypertension and Preeclampsia. IMA Kerala Medical Journal. 2019 Jun 24;12(2):46-9.

### Corresponding Author:

Dr Manjusha Viswanathan, Associate professor, Department of Obstetrics and Gynecology, Sree Gokulam Medical College & Research Foundation, Venjaramoodu. E-mail: manjuvishy94@gmail.com

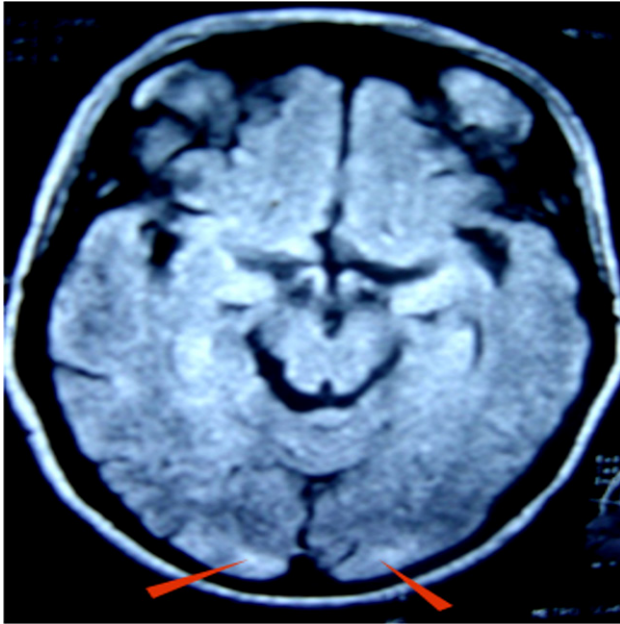


Figure 1. Hyper-intense lesion in both right and left occipital lobe

of vision in both eyes with a BP of 180/120mm Hg, and no perception of light in both eyes. The anterior segment was within normal limits, and both direct and consensual reaction of pupil was normal in both eyes. Also the dilated fundus examination was within normal limits in both eyes. Neurological examination revealed absence of long tract signs, absence of neck stiffness, normal pupillary reflex and preservation of higher mental functions with signs of cortical blindness. Emergency MRI revealed high intensity signals involving sub cortical white matter in both occipital lobes, diagnostic of PRES.

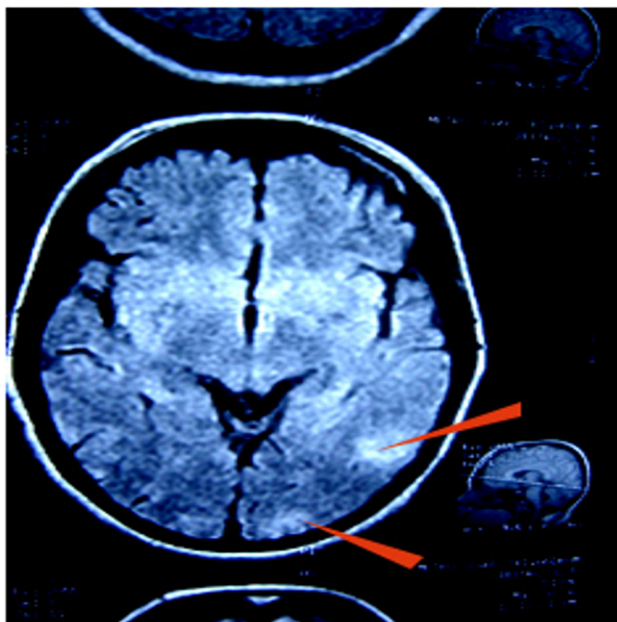


Figure 2. MRI shows flair axial section showing two hyper-intense lesions in the left occipital lobe

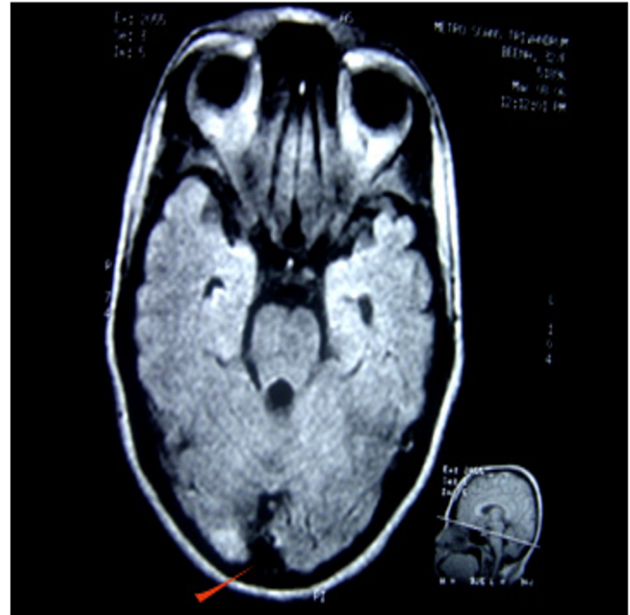


Figure 3. MRI Flair axial section showing Hyper intense lesion in the right occipital lobe

Blood pressure was controlled with atenolol 25mg and amlodipine 5 mg daily. She was started on IV mannitol and other symptomatic measures. The clinical improvement was noticed within 48 hours and her vision improved to 6/6 by 4th day of diagnosis. On follow up after six weeks, she has no neurological sequelae and has normal fields of vision.

## DISCUSSION

Posterior reversible encephalopathy syndrome (PRES) is a recently proposed clinical neuro-radiologic syndrome.<sup>6,7</sup> It is characterized by seizures, disorders of consciousness, visual abnormalities and headaches associated with predominantly posterior white matter abnormalities on CT and MRI examinations. Common inciting factor of PRES are acute elevations of blood pressure, renal decompensation, fluid retention, and treatment with immunosuppressive drugs.<sup>1</sup> The inciting factor of PRES includes; acute elevation of blood pressure, renal compensation, fluid retention and treatment with immune-suppressive drugs.

The most common clinical symptoms and signs are headache, altered alertness and behavior; ranging from drowsiness to stupor, seizures, vomiting, mental abnormalities including confusion and diminished spontaneity of speech, and abnormalities of visual perception. The onset of symptoms may be sub-acute but it may be heralded by the occurrence of a seizure. Seizures can occur at the onset or at a later stage. Usual signs present with it is lethargy and somnolence but stupor and frank coma may also be the presenting signs. Some

Symptoms	signs
Thunder Clap Headache	Altered alertness
Vomiting	Drowsiness
Mental abnormalities	Stupor
Decreased spontaneity of speech	Seizures Visual abnormalities

patients have coordination abnormalities and weakness of limbs with brisk tendon reflexes. Signs of visual abnormalities may include visual neglect, hemianopia and frank cortical blindness.<sup>1</sup>

Neuro-imaging is indicated in patients presenting with altered consciousness in pregnancy and if there are atypical features or visual disturbance in patients with eclampsia in both antenatal and postnatal period and the MRI is the imaging modality of choice.<sup>8,9</sup> It is important to distinguish PRES from acute ischemic stroke. Hypertension in ischemic stroke should not be managed aggressively but in PRES; active management and control of hypertension is the treatment of choice.<sup>5</sup> During the acute phase neuro-imaging would reveal edema involving the white matter in the posterior portion of the cerebral hemisphere, especially bilateral in the parieto-occipital regions. The calcarine and paramedian occipital lobe structures are usually spared, a feature that distinguishes reversible posterior leukoencephalopathy from bilateral infarction of the posterior-cerebral artery territory.<sup>7,10</sup> Hypertensive encephalopathy is the etiology for this condition.

Hypertensive encephalopathy and preeclampsia/eclampsia share similar patho-physiological mechanism.<sup>11</sup> Sudden elevations in the systemic blood pressure exceed the auto regulatory capability of the brain vasculature and there is break down of the blood brain barrier with focal transduction of fluid and petechial hemorrhages. Disappearance of the clinical signs and imaging abnormalities after control of hypertension suggests towards edema as the cause.<sup>12</sup> Microscopically, these petechiae are ring hemorrhages around capillaries and precapillaries, which are occluded by fibrinoid material. The susceptibility of the posterior portion of the brain to the lesions seen in hypertensive encephalopathy and eclampsia is recognized, and this is probably because the vertebra-basilar vessels are relatively devoid of sympathetic innervations and results in the loss of auto regulation and forced arteriolar dilatation predominantly in watershed occipital lobe.

The differential diagnosis of PRES includes; infarcts, including “top of basilar syndrome”, venous thrombosis,

infections-meningitis encephalitis, post infectious encephalomyelitis and vasculitis, epinephrine induced.<sup>13</sup> PRES is a devastating uncommon condition which has excellent prognosis if treated actively. In patients with eclampsia and severe preeclampsia, magnesium sulphate treatment is started either at onset of seizure or prophylactically. As preeclampsia is a progressive condition, the prognosis will be poor if pregnancy continues. Hence delivery of the fetus is the definitive management along with control of blood pressure and control of seizures. If the patient presents before 34 weeks of pregnancy the delivery may be delayed for 24-48 hrs for the action of corticosteroids to set in.<sup>14</sup> With this management the morbidity of PRES can be brought down. Aggressive anti hypertensive treatment is started in all patients with systolic blood pressure of 170 mm of Hg or a diastolic blood pressure of over 110 mm of Hg.<sup>14</sup> The drugs for treatment of hypertension in pregnancy have been subjected to Cochrane review, and shows that there is no advantage of one drug over the other.<sup>15</sup> The aim of pharmacological treatment is to maintain the blood pressure systolic between 140 and 160mm of Hg and diastolic between 90 -105 mm Hg.

Three cases were reported by magi et al in 2013, the first case is a 29 year old lady, who had seizures at 35 weeks of gestation and pregnancy was terminated by caesarean section due to eclampsia and developed PRES after that.<sup>16</sup> The second patient was a 45 year old patient at 39 weeks of gestation who had severe oedema antenataly with no prior blood pressure elevation, developed seizures and the pregnancy was terminated by caesarean section. Six hours after caesarean section she had focal changes in the MRI, diagnostic of PRES. The third patient was a 35 year old second gravida with one live child, who had no prior elevated blood pressure. She developed blood pressure elevation during labor and had seizures two hours after delivery. She had focal neurological deficit and mild limb edema.<sup>16</sup> In all these cases, the presenting feature was seizure.

Our patient developed PRES in the puerperium, rather than during pregnancy. There was massive fluid accumulation in extracellular spaces and hemo-concentration in pregnancy, complicated by preeclampsia. During puerperium, there was fluid shift back to intravascular space; this may have accentuated the tendency for brain edema to develop. As our patient presented post-natally she was treated with amlodipine and atenolol for control of blood pressure. Prompt control of blood pressure is essential for the management of this condition.

## CONCLUSION

RPLS or PRES though reversible, if left untreated; the arterial hypertension can lead to progressive neurological deterioration with infarction, hemorrhage and possible irreversible neurologic deficit. The exact time interval between the diagnosis, control of blood pressure and the permanent damage has not been studied. Therefore, PRES is added to the list of indication for termination of pregnancy in patients with preeclampsia. Prompt diagnosis and strict control of blood pressure is of paramount importance in this condition. Early recognition and treatment can save patient's vision and avoid morbidity due to neurological deficits

## END NOTE

### Author Information

1. Dr Bindu Thampi  
Associate professor  
Department of Ophthalmology  
Sree Gokulam Medical College & Research  
Foundation, Venjaramoodu
2. Dr Manjusha Viswanathan  
Associate professor  
Department of Obstetrics and Gynecology  
Sree Gokulam Medical College & Research  
Foundation, Venjaramoodu.
3. Dr Suja Daniel, Professor  
Department of Obstetrics and Gynecology  
Sree Gokulam Medical College & Research  
Foundation, Venjaramoodu
4. Dr Manoj P, Associate professor  
Department of Medicine  
Sree Gokulam Medical College & Research  
Foundation, Venjaramoodu

**Conflict of Interest:** None declared

## REFERENCES

1. Hinchey J, Chaves C, Appignami B. A reversible posterior leukoencephalopathy syndrome. *N Engl J Med.* 1996;334:494–500.
2. Hara N, Fugii T, Tsutsumi O. Postpartum eclampsia associated with cortical blindness. *Int J Obstet Gynecol.* 1994;47:287–8.
3. Casey SO, Sampaio RC, Michel E, Truwit CL. Posterior reversible encephalopathy syndrome: Utility of fluid-attenuated inversion recovery MR imaging in the detection of cortical and subcortical lesions. *Am J Neuroradiol.* 2000;21:1199–206.
4. Autunes NL, Small TN, George D, Boulad F, Lis E. Posterior leukoencephalopathy syndrome may not be reversible. *Pediatr Neurol.* 1999;20:241–3.
5. Stott VL, Hurrell MA, Anderson TJ. Reversible posterior leukoencephalopathy syndrome: A misnomer reviewed. *Int Med J.* 2005;35:83–90.
6. Cunningham F G, Fernandez C O, Hernandez C. Blindness associated with preeclampsia and eclampsia. *Am J Obstet Gynecol.* 1995;172 (4 Pt 1):1291–1298.
7. Lamy C, Mas JL. Reversible posterior leukoencephalopathy. A new syndrome or a new name for an old syndrome? *Presse Med.* 2001 May 19;30(18):915–20.
8. Karnal DR, Guntupalli KK. Neurologic disorders in pregnancy. *Crit Care Med.* 2005;33:362–71.
9. Chambers KA, Cain TW. Postpartum blindness: Two cases. *Ann Emerg Med.* 2004;43:243.
10. Duncan R, Hadley D, Bone I, Symonds EM, Worthington BS, Rubin PC. Blindness in eclampsia: CT and MR imaging. *J Neurol Neurosurg Psychiatry.* 1989;52:899–902.
11. Sibai BM, Schneider JM, Morrison JC. The late postpartum eclampsia controversy. *Obstet Gynecol.* 1980;55:74–8.
12. BB J. The blood-brain barrier and cerebral blood flow in acute hypertension. *Acta Med Scand Suppl.* 1983;678:107–112.
13. Prout RE, Tuckey JP, Giffen NJ. Reversible posterior leukoencephalopathy syndrome in a peripartum patient. *Int J Obstet Anesth.* 2007;16:74–6.
14. Duley L., Henderson-Smart DJ, Meher S. Drugs for treatment of very high blood pressure during pregnancy. *Cochrane Database Syst Rev.* 2006;3:CD001449.
15. Hutcheon JA, Lisonkova S, Joseph KS. Epidemiology of pre-eclampsia and the other hypertensive disorders of pregnancy. *Best Pr Res Clin Obstet Gynaecol.* 2011;25:391–403.
16. Casey SO, Sampaio RC, Michel E, Truwit CL. Posterior reversible encephalopathy syndrome: Utility of fluid-attenuated inversion recovery MR imaging in the detection of cortical and subcortical lesions. *Am J Neuroradiol.* 2000;21:1199–206.