

Giant Left Atrial Myxoma Causing Mitral Inflow and Pulmonary Venous Obstruction

George Joseph Valooran^a, Praveen Kerala Varma^a

a. Division of Cardiac surgery, Sree Chitra Tirunal Institute for Medical Sciences and Technology Trivandrum, India*

ABSTRACT

Published on 24th December 2018

Introduction and Objective: Atrial myxomas are the most common primary cardiac tumors. Here we report a giant left atrial myxoma with mitral inflow and pulmonary venous obstruction and treated successfully by surgical resection Case report: a large left atrial (LA) myxoma of size 9x3.4 cm occupying almost the entire LA with prolapse into the mitral inflow during atrial systole. The soft lobulated tumor was excised with a wide cuff of IAS circumferentially through a bi-atrial approach (Trans right atrial (RA) and LA). CABG was also performed using Left Internal mammary artery Discussion: Once a cardiac myxoma is diagnosed it requires surgical excision, and in the event of a large mass, RA access alone does require significant tumor manipulation and may not permit radical resection

Conclusion: bi-atrial approach ensures good exposure and enables radical excision of the tumor.

Keywords: Myxoma, Atrial, Atrial, Cardiac Tumor, LA Myxoma

*See End Note for complete author details

INTRODUCTION

Atrial myxomas are the most common primary cardiac tumors. They are usually small or moderate in size at the time of diagnosis and exhibit non specific cardiac or non cardiac symptoms.¹ Large atrial myxomas have been reported sporadically.² Here we report a giant left atrial myxoma with mitral inflow and pulmonary venous obstruction and treated successfully by surgical resection.

CASE PRESENTATION

48 year old man presented with complaints of FC II Dyspnea on exertion of 6 months duration with no

other comorbidities. He was evaluated with Trans Thoracic Echocardiography (TTE) which revealed a large 8 x 3 cm mass attached-to the left atria (LA) side of Inter Atrial Septum (IAS) with intrinsic mobility and prolapse into the mitral inflow channel during atrial systole causing moderate to severe systolic obstruction. The mass was noted to prolapse in and out of mitral inflow channel during atrial systole and diastole. LA was moderately enlarged and hypertrophic. Mitral valve (MV) was structurally normal with no Mitral Regurgitation (MR). Coronary angiography revealed double vessel disease involving proximal Left Anterior Descending (LAD) and ramus intermedius. He was referred to undergo Myxoma excision and concomitant

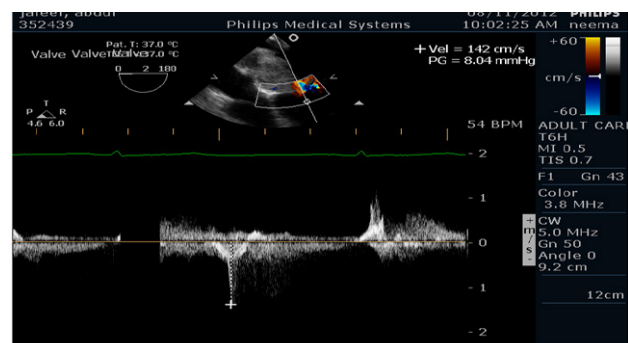
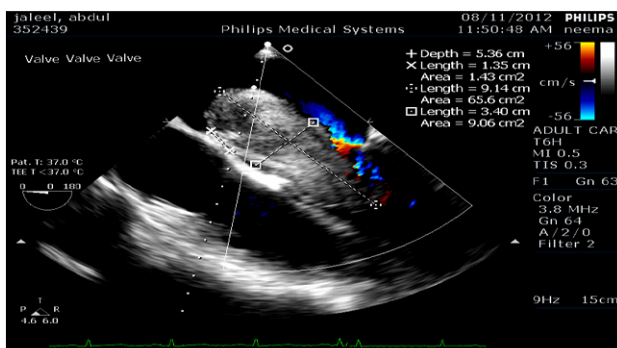


Figure 1 & 2. Intraoperative Trans Esophageal Echocardiography (TEE) of LA myxoma

Cite this article as: Valooran GJ, Varma PK. Giant Left Atrial Myxoma Causing Mitral Inflow and Pulmonary Venous Obstruction. IMA Kerala Medical Journal. 2018 Dec 24;11(4):115-7.

Corresponding Author:

Dr Praveen Kerala Varma, Additional Professor, Senior resident, Division of Cardiac surgery, Sree Chitra Tirunal Institute for Medical Sciences and Technology, Trivandrum, India. E-mail: varmapk@gmail.com

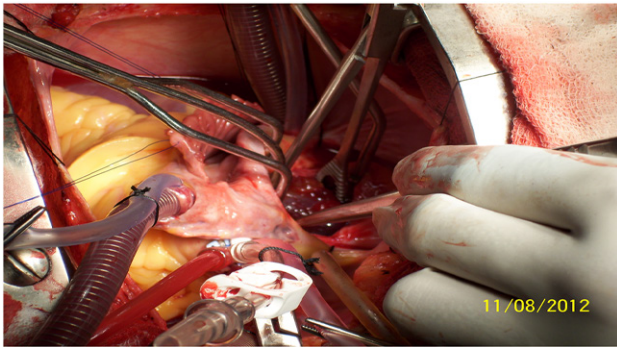


Figure 3. 9x 3.4 cm LA myxoma approached bi-atrially

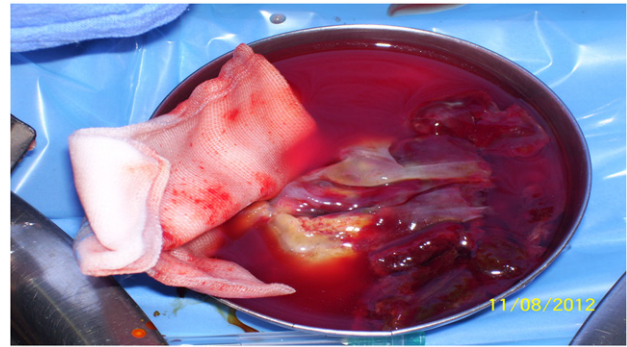


Figure 3. Excised LA Myxoma

coronary artery bypass grafting (CABG).

Intraoperative Trans Esophageal Echocardiography (TEE) revealed a large LA myxoma of size 9x3.4 cm occupying the almost the entire LA with prolapse into the mitral inflow during atrial systole (**Figures 1 & 2**).

The tumor was found obstructing the pulmonary vein orifices. 8x 3.4 cm soft lobulated tumor was excised with a wide cuff of IAS circumferentially (**Figures 3 & 4**) through a Bi-atrial approach (Trans RA and LA). CABG was also performed using Left Internal mammary artery. Post-operative course was uneventful. TTE done on 5th day revealed no residual tumor mass and normal MV anatomy and function. There was no MR and MV mean gradient was 3. He was discharged on 10th day with stable vitals.

DISCUSSION

Atrial myxomas are slow growing tumors usually arising from IAS and extending onto Left or right atrium and are considered benign. Eighty five percent are located in the LA, the remaining 15 % in the right atrium, in both atria and ventricles.¹ Clinical symptoms are related to embolic events or obstructive valve dysfunction. About 4 % of patients are asymptomatic.³ The three classical clinical features at presentation include Mitral valve

obstruction, Embolic episodes and constitutional symptoms.⁴ The classical 'Tumor plop' is rare and reported only in 15 % of patients. ECG might show evidence of LA Hypertrophy, TTE and Cardiac MRI are diagnostic tools of choice. Once a cardiac myxoma is diagnosed it requires surgical excision. Most of the myxomas arise from IAS and hence is approached through RA and involves excision of IAS and ensuing defect is usually patched with autologous pericardium.

However in the event of a large mass, RA access alone does require significant tumor manipulation and may not permit radical resection. Similarly, a right atriotomy with septal incision may not accommodate removal of a large tumor mass without fragmentation.² Bi-atrial approach ensures good exposure and enables radical excision of the tumor and reduces its manipulation, and at the same time permits exploration of all 4 chambers.^{2,5,6} Potential complications associated with the bi-atrial approach include supraventricular arrhythmias, conduction disturbances, and postoperative left-to-right shunting.²

Although there have been sporadic reports of large LA myxomas, we present here a case of unusually large LA myxoma of size 8x5 cm occupying the entirety of LA with mitral inflow obstruction. The symptomatology of the patient could be related to the mitral inflow obstruction and pulmonary venous obstruction due to the LA myxoma. The mass although sessile was having intrinsic mobility which allowed it to prolapse into the mitral inflow channel during atrial systole. The same tumor produced pulmonary venous obstruction during atrial diastole thus elevating the Pulmonary artery pressure.

The long-term prognosis is excellent after surgery for myxoma excision. The recurrence rate is low (5%), but long-term follow-up and serial echocardiography are advisable.

CONCLUSION

A giant left atrial myxoma causing mitral inflow and pulmonary venous obstruction need bi-atrial approach which ensures good exposure and enables radical excision of the tumor. This reduces the manipulation of mass, and at the same time permits exploration of all 4 chambers.

END NOTE

Author Information

1. Dr George Joseph Valooran
Senior resident, Division of Cardiac surgery
Sree Chitra Tirunal Institute for Medical Sciences
and Technology
Trivandrum, India
2. Dr Praveen Kerala Varma
Additional Professor, Senior resident
Division of Cardiac surgery
Sree Chitra Tirunal Institute for Medical
Sciences and Technology
Trivandrum, India.

Conflict of Interest: None declared

REFERENCES

1. Reynen K. Cardiac myxomas. *New Eng J Med* 1995, 333:1610-1617.
2. Davoli G, Luigi M, Lucchesse G, Uricchio N, Chiavarelli M. Large atrial myxoma with severe mitral regurgitation. The inverted T shaped biatrial incision revisited. *Tex Heart Inst J* 2006; 33(1):51-53.
1. Kabbani SS, Cooley DA. Atrial myxoma. Surgical considerations. *J Thorac Cardiovasc Surg* 1973;65:731-7.
3. Meng Q, Lai H, Tong W, Qian Y, Lai Echocardiographic and pathologic characteristics of primary cardiac tumors: a study of 149 cases. *Int J Cardiol* 2002, 84:69-75.
4. Pinede L, Duhaut P, Loire R. Clinical presentation of left atrial cardiac myxoma. A series of 112 consecutive cases. *Medicine (Baltimore)*. 2001;80 (3):159-72.
5. Jones DR, Warden HE, Murray GF, Hill RC, Graeber GM, Cruzzavala JL, et al. Biatrial approach to cardiac myxomas: a 30-year clinical experience. *Ann Thorac Surg* 1995;59: 851-6.
6. Morishita K, Fukada J, Abe T. Inverted T-shaped biatrial incision for large left atrial myxoma. *J Card Surg* 1997;12: 112-5.