

Sepsis due to *Roseomonas Gilardii* in an Elderly Female

Ashna Ajimsha^a, Ashish Jitendranath^a, Ivy Vishwamohanan^a

a. Department of Microbiology, Sree Gokulam Medical College and Research Foundation, Venjaramoodu, Thiruvananthapuram*

ABSTRACT

Published on 14th September 2020

An 82 year old female, who is a known case of osteoarthritis on medications, presented to her physician with a two day history of urinary retention, constipation, abdominal discomfort and worsening of breathlessness which started one week ago. On clinical examination, she was conscious, oriented, had pallor and bilateral pedal edema. Her vitals were stable. She was febrile. A positive growth was detected on BacT/ALERT 3D. The gram stain smear of blood culture broth showed gram negative bacilli which was identified as *Roseomonas gilardii*

Keywords: Sepsis, *Roseomonas Gilardii*, Elderly sepsis

*See End Note for complete author details

An 82 year old female, who is a known case of osteoarthritis on medications, presented to her physician with a two day history of urinary retention, constipation, abdominal discomfort and worsening of breathlessness which started one week ago. She gave a history of abdominal distension since ten years which was insidious in onset, gradually progressive and associated with breathlessness and chest discomfort. She was diagnosed to have acute severe asthma and was managed with bronchodilators, antihistamines and other supportive measures, one week ago at another hospital.

On clinical examination, she was conscious, oriented, had pallor and bilateral pedal oedema. Her vitals were stable. She was febrile (Temp was 102.5 degree Fahrenheit). On auscultation, crepitations were heard in the infra scapular region. Her abdomen was distended with diffuse tenderness and a palpable liver. Per rectal examination was suggestive of ballooning and faecal staining.

She was admitted and routine investigations were done. Her total counts were elevated (14,500 cells/microlitre). Her CRP values were raised (14.71mg/dl). Peripheral smear was suggestive of microcytic hypochromic anaemia and neutrophilic leucocytosis. USG abdomen was suggestive of chronic liver disease with moderate ascites. Ascitic fluid was sterile. Spontaneous bacterial peritonitis was ruled out. Her serum amylase and lipase levels were elevated. A diagnosis of acute pancreatitis was made after General Surgery consultation. She was kept NPO and given IVF for 36 hours. Repeated lipase levels were within

normal limits. Her renal function tests were deranged for which Nephrology consultation was done and she was advised salt and fluid restriction and diuretics. She was initially managed with IV Tazomac 2.25 g q8h for 5 days.

A positive growth was detected on BacT/ALERT 3D. The gram stain smear of blood culture broth showed gram negative bacilli. Subcultures were done on blood agar, chocolate agar and Mc Conkey agar as per protocol. After incubation for 24 hours the cultures showed no growth, however after 48 hours of incubation at 37°C, pink pigmented colonies grew on both blood agar and chocolate agar (**Figure 1**). On Mc Conkey agar, the growth was scanty and took around 72 hours of incubation. Catalase test was positive and oxidase test was delayed. Organism was a non fermentor (**Figure 2**). On VITEK 2 automated system, the organism was identified as *Roseomonas gilardii* with 99% probability and excellent identification. The isolate was susceptible to Amoxicillin Clavulanic acid, Tetracycline, Cotrimoxazole, Ciprofloxacin, Gentamicin, Netilmicin, Amikacin, Colistin, Tigecycline, Imipenem, Meropenem, Ofloxacin and Aztreonam. It was resistant to Ampicillin, Piperacillin, Piperacillin Tazobactam and Cephalosporins.

Antibiotic was changed to Inj. Meropenem 500mg IV q8h. Venous Doppler of both lower limbs were suggestive of chronic Deep vein thrombosis for which heparin was given. She improved clinically and symptomatically, tolerating oral feeds, afebrile, no orthopnoea and had adequate urine output at the time of discharge.

Cite this article as: Ajimsha A, Jitendranath A, Vishwamohanan I. Sepsis due to *Roseomonas Gilardii* in an Elderly Female. IMA Kerala Medical Journal. 2020 Sep 14;13(3):116–8.

Corresponding Author:

Dr Ashish Jitendranath, Professor, Department of Microbiology, Sree Gokulam Medical College and Research Foundation, Venjaramoodu, Thiruvananthapuram, Kerala 69607. E-mail: ashna.ajim@gmail.com

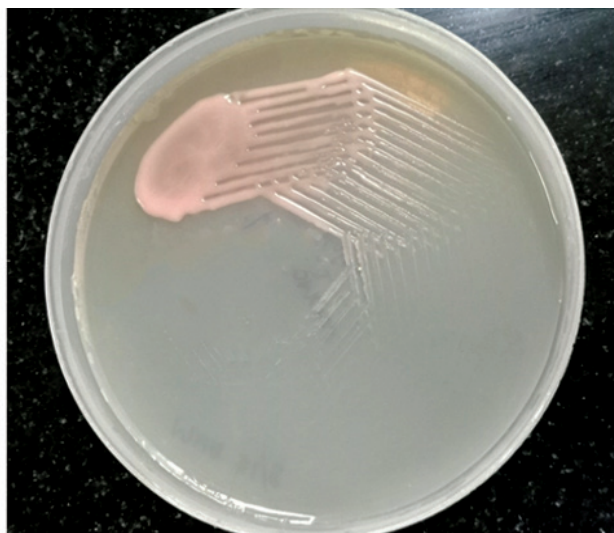


Figure 1. Pink pigmentation and Mucoïd character of *Roseomonas gilardii*. Pigmentation developed after 72 hours of incubation

DISCUSSION

Gilardi and Faur studied 21 pink-pigmented gram-negative rods, reporting seven of them as an unnamed taxon, because they did not fit into any previously described species and they differed from *Methylobacterium mesophilicum*¹ on the basis of Gram stain morphology, growth at 42°C, growth on MacConkey agar, acetate utilization, and acid production from methanol² and then it was defined by the Centers for Disease Control and Prevention to indicate these bacteria in 1984.³ In 1989, Korvick and colleagues reported two cases of pink-pigmented gram-negative isolates. In the largest review of pink-pigmented bacteria, Wallace and co-workers studied 156 isolates received at the CDC since 1966 and defined four heterogeneous “pink coccoid” groups (I through IV).¹

The bacterial genus *Roseomonas* encompasses four species (*Roseomonas gilardii*, *Roseomonas mucosa*, *Roseomonas cervicalis* and *Roseomonas fauriae*), and was first classified by Rihs and colleagues in 1993 (Rihs et al. 1993). They have been isolated from the aquatic environment. The organisms have been isolated from blood, wound, urinary and respiratory specimens, peritoneal dialysis fluid, corneal scrapings and bones. Though, *Roseomonas* species appear to have low pathogenic potential, some species may cause clinically significant or even fatal disease in immunocompromised patients like those with leukemia, septicemia, cancer chemotherapy and dialysis.⁴

Roseomonas is a pink-pigmented, non-fermentative, oxidase positive, slow growing Gram-negative coccobacilli that has clinical importance as opportunistic bacteria which can lead to infections especially in immunosuppressed individuals. Most infections due to *Roseomonas* species are detected in patients with central venous catheters and underlying disorders. It is less reported in many hospitals



Figure 2. Biochemical reactions of *Roseomonas gilardii*

because of having little experience in identification and less clinicians dealing with these infections. They are detected after several days of growth in culture environment, characteristic pink, mucoid colonies are observed. The clinical specimens in which the microorganism was isolated include wounds, exudates, abscesses and genitourinary specimens. Besides, infection can be related with peritoneal dialysis and vertebral osteomyelitis. The clinical importance of these isolates is an essential issue in individuals with underlying disorders such as cancer and diabetes and in a study that reviewed of 35 cases from which *Roseomonas* strains were isolated, 60% were found to be related with disease.³

Due to the rarity of this infectious agent, it may be overlooked from a clinical and microbiological perspective. A method to identify organisms collected from sterile sites, such as the Vitek 2 system (bioMe'rieux), might not correctly identify *Roseomonas* species. For such species after several days growth in an appropriate culture environment, characteristic pink, mucoid colonies are seen.⁵ They grow on 5% sheep blood agar, chocolate agar, buffered charcoal-yeast extract agar, and almost always (91%) on MacConkey agar but do not grow on media containing greater than 6% NaCl. *Roseomonas* species grow at 25, 30, 35, and usually 42°C. Motility, nitrate reduction, and oxidation of L-arabinose, D-galactose, D-glucose, D-mannose, D-mannitol, and D-xylose are variable characteristics.⁶

END NOTE

Author Information

1. Dr Ashna Ajimsha, Department of Microbiology, Sree Gokulam Medical College and Research Foundation
2. Dr Ashish Jitendranath, Professor, Department of Microbiology, Sree Gokulam Medical College and Research Foundation, Venjaramoodu, Thiruvananthapuram, Kerala 69607.

3. Dr Ivy Vishwamohan, Department of Microbiology, Sree Gokulam Medical College and Research Foundation.

Conflict of Interest: None declared

REFERENCES

1. Marin EM et al; catheter-related-bacteremia-caused-by-roseomonas-gilardii-in-an-immunocompromised-patient. *Int J Infect Dis.* 2001;5(3):170–1.
2. Rihs JD, Brenner DJ, Weaver RE, Steigerwalt AG, Hollis DG, Yu VL. *Roseomonas*, a new genus associated with bacteremia and other human infections. *J Clin Microbiol.* 1993 Dec;31(12):3275–83.
3. Ece G, Ruksen M, Akay A. Case report: cranioplasty infection due to *Roseomonas gilardii* at a university hospital in turkey. *Pan Afr Med J [Internet].* 2013 [cited 2019 Oct 13];14.
4. Mamtora DK, Mehta P, Bhalekar P. *Roseomonas Gilardi* Bacteremia in a Pediatric Oncology Patient on Chemotherapy: A Rare Case Report. *Indian J Neonatal Med Res.* 2017;5:3.
5. Fanella S, Schantz D, Karlowsky J, Rubinstein E. Septic arthritis due to *Roseomonas gilardii* in an immunocompetent adolescent. *J Med Microbiol.* 2009 Nov 1;58(11):1514–6.
6. Sandoe JA, Malnick H, Loudon KW. A case of peritonitis caused by *Roseomonas gilardii* in a patient undergoing continuous ambulatory peritoneal dialysis. *J Clin Microbiol.* 1997 Aug;35(8):2150–2.