

Unusual Presentation of Multiple Myeloma

P Baburaj^a, Lincy Paul^b, Harikrishnan M P^b

a. Department of Medicine, Jubilee Mission Medical College, Thrissur, Kerala;

b. PG student, Jubilee Mission Medical College Thrissur, Kerala*

ABSTRACT

Published on 27th September 2018

64 years old diabetic male presented with 2 months history of back ache, associated with restriction of movements, involving paraspinal muscles. Investigations showed pancytopenia, high ESR, bone marrow examination was suggestive of multiple myeloma. Serum electrophoresis showed no abnormal band. And the patient was diagnosed to have non secretory myeloma presenting as polymyalgia rheumatica.

Keywords: Polymyalgia Rheumatica, Non-secretory Myeloma

*See End Note for complete author details

INTRODUCTION

Non secretory myeloma is a rare variant of multiple myeloma which accounts for 1-5% of all multiple myeloma.¹ It is characterized by absence of monoclonal Immunoglobulins in serum or urine.^{2,3} Polymyalgia rheumatica is a rheumatological disease which can be a paraneoplastic manifestation of multiple myeloma.⁴ Here we report a case of non-secretory myeloma presenting as polymyalgia rheumatica.

CASE REPORT

64 years old diabetic patient who is an ex-smoker presented with 2 months history of severe back pain, pain bilateral pectoral girdle, paraspinal muscles of dorsal region and pelvic girdle which aggravates with movement. There was restriction of spinal movements due to pain. There was no history suggestive of radicular pain. No history of fever, headache or loss of weight. He has past history of bilateral renal stones.

Physical examination showed pallor and bilateral pitting pedal oedema. No clubbing or lymphadenopathy. Pulse - 86 beats/min, regular, low volume, B.P - 140/80 mm Hg.

Systemic examination showed restriction of movements of pelvic girdle, proximal muscles of upper limb and lower limb, paraspinal muscles of dorsal region, limitation of spinal movements. Loss of lumbar lordosis. Hip movements were normal and no major disability. No root stretch signs and no neurological deficit.

Central Nervous System - normal higher mental functions, normal reflexes, Cardiovascular System - within normal limits, Respiratory System - within normal limits, Gastrointestinal system - no hepatosplenomegaly.

He was investigated outside in a tertiary care centre. Outside investigations were showing pancytopenia, ESR - 19 mm/hour, CRP - 2.3, S. PSA - 2.53, GGT - 38, S. Calcium - 10.1 mg/dl, S. Phosphorus - 3.7 mg/dl, Uric acid - 3.7 mg/dl, LDH - 154, Reticulocyte count - 2%, Serum electrophoresis - No M band. USG abdomen showed Grade II BPH, Grade I fatty liver, Right renal cortical cyst. MRI spine showed straightening of lumbar spine, suggestive of paraspinal muscle spasm, Cervical spondylosis, Asymmetric disc bulge at L2-L3 level and bilateral grade I neural foraminal narrowing & grade II narrowing at L3-L4 level.

Investigations done in our centre: Hb - 10.6 g/dl, TC - 2280 cells/cumm, ESR - 62 mm/hr, platelet - 1,00,000 cells/cumm, DC - N56 L34 E1 M7, HCT - 31%, MCV - 93.4, MCH - 31.9, MCHC - 34.2, SGOT - 21 mg/dl, SGPT - 11 mg/dl, Alkaline phosphatase - 128 mg/dl, S. Protein - 6.6 mg/dl, S. Albumin - 4.4 mg/dl, S. Globulin - 2.2 mg/dl RFT - within normal limits, S. Calcium - 10.3 mg/dl, S. Sodium - 138 mg/dl, S. Potassium - 3.9 mg/dl, Urine BJP - Negative, CPK - 102, S. Iron - 57, S. Ferritin - 779, TSH - 2.96, S. Vitamin B12 - low normal, 24 hour urine protein - 359, X ray skull - punched out osteolytic lesions, Peripheral smear - Dimorphic blood picture, normocytic and

Cite this article as: Baburaj P, Paul L, Harikrishnan MP. Unusual Presentation of Multiple Myeloma. Kerala Medical Journal. 2018 Sep 27;11(3):80-2.

Corresponding Author:

Dr. Lincy Paul, PG student, Jubilee Mission Medical College, Thrissur, Kerala.
Mobile: 9447122857. E-mail: lincypaul11@gmail.com

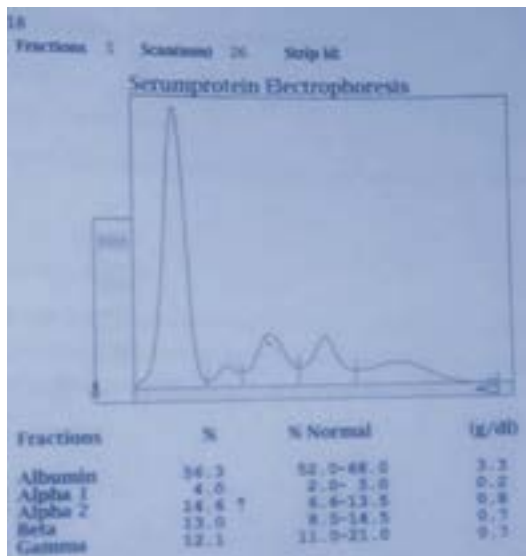


Figure 1. Hypoproteinemia and no abnormal bands

macrocytic, mild leukopenia and thrombocytopenia, Bone marrow aspiration and biopsy was suggestive of multiple myeloma, Serum Electrophoresis showed hypoproteinemia, no abnormal bands (figure 1). Immunohistochemistry CD 138 positive, Kappa is negative, Lambda light chain restriction, MUM1 positive –suggestive of multiple myeloma. Final diagnosis is non-secretory myeloma presenting as polymyalgia rheumatica.

DISCUSSION

Non secretory myeloma is defined by the absence of serum or urinary or both monoclonal immunoglobulins in patients who otherwise manifest features typically found in multiple myeloma. It results either from the inability of malignant plasma cells to synthesize immunoglobulin or more commonly the failure of such components to be exported from the cells.^{2,3} Non secretory myeloma is a rare variant of multiple myeloma which accounts for 1-5%.¹ Two distinct types of non-secretory myeloma described are true or producer type and non-producer type. In true type, plasma cells produce immunoglobulins but are unable to secrete it out of the cell. In non-producer type, plasma cells are unable to produce immunoglobulins.^{5,6} In our case, 64 years old patient presented with 2 months history of back ache,

Table 1. Criteria for Non-Secretory Myeloma

Biopsy-proven clonal plasma cells
<0.5 mg/dL serum protein by SPEP
< 200 mg/24 hrs of light chain proteinuria by UPEP
Unquantifiable free light chain measurement
Evidence of CRAB criteria for symptomatic myeloma (which must be attributable to clonal plasma-cell infiltration)
CRAB criteria = hypercalcemia, renal dysfunction, anemia, bone disease; SPEP = serum protein electrophoresis; UPEP = urine protein electrophoresis

associated with restriction of movements. Investigations showed pancytopenia, high ESR, bone marrow examination was suggestive of multiple myeloma. Serum electrophoresis showed no abnormal band. All these findings are consistent with non-secretory myeloma. Diagnostic criteria of non secretory myeloma are given in Table 1.

Non metastatic manifestations of multiple myeloma⁷

1. Anaemia, which is usually normocytic normochromic and is due to tumor cell involvement of marrow and inadequate erythropoietin responsiveness.
2. Renal failure, etiology is multifactorial. Most common causes are interstitial nephritis, hypercalcemia, impaired glomerular filtration, AL amyloidosis. Other causes of renal failure are use of non-steroidal anti-inflammatory drugs, hyperuricemia, intravenous contrast for radiographic studies, bisphosphonate therapy, renal calculi and nephrotoxic chemotherapeutic agents.
3. Hypercalcemia, due to unbalanced increased osteoclast and suppressed osteoblastic activity.
4. Infections, due to deficiency of humoral and cellular immunity. High dose corticosteroids also play role.
5. Neurologic symptoms like Polyneuropathy, Organomegaly, Endocrinopathy, Monoclonal gammopathy, Skin changes (POEMS).
6. Hyperviscosity
7. Coagulopathy.
8. Polymyalgia rheumatica.⁴

Diagnostic criteria of polymyalgia rheumatica⁸

Criteria of Chuang & Colleagues(1982)

1. Age 50 years or older.
2. Bilateral aching and stiffness for 1 month or more and involving 2 of the following areas: Neck or torso, shoulders or proximal regions of the arms and hips or proximal aspects of the thighs.
3. ESR >40mm/hour.
4. Exclusion of all other diagnosis except giant cell arteritis.

Criteria of Healey (1984)

1. Pain persisting for at least 1 month and involving 2 of the following areas: neck, shoulders and pelvic girdle.
2. Morning stiffness lasting >1 hour.
3. Rapid response to prednisone (20 mg/day or less).

4. Absence of other diseases capable of causing the musculoskeletal symptoms.
5. Age >50 years.
6. ESR >40 mm/hour.

Etiology of polymyalgia rheumatica⁹

Genetic causes: associated with HLA DRB1*04 and HLA DRB1*01

Infectious causes: Adenovirus

Para influenza virus type 1

Parvovirus B19

Mycoplasma pneumonia

Chlamydia pneumonia

Hormones: Adrenal gland hypofunction

CONCLUSION

We report a case of multiple myeloma, non-secretory type with para neoplastic manifestation presenting as polymyalgia rheumatica.

END NOTE

Author Information

1. Prof. Dr. P. Baburaj, Professor,
Department of Medicine,
Jubilee Mission Medical College, Thrissur, Kerala.
2. Dr. Lincy Paul, PG student,
Jubilee Mission Medical College Thrissur, Kerala.

3. Dr. Harikrishnan M P, PG student,
Jubilee Mission Medical College Thrissur, Kerala.

Editor's Remarks: This case report adds to our knowledge about Multiple Myeloma. This variant Non secretory Multiple Myeloma has several unusual features. To know about this please read this article.

Conflict of Interest: None declared

REFERENCES

1. Kyle RA, Gertz MA, Witzig TE, Lust JA, Lacy mQ, Dispenzieri A et al. Review of 1027 patients with newly diagnosed multiple myeloma. Mayo Clin Proc 2003; 78: 21-33.
2. Cavo M, Galieni P, Gobbi M, Baldrati L, Leardini L, Baccarani M, et al. Nonsecretory multiple myeloma. Presenting findings, clinical course and prognosis. Acta Haematol. 1985;74(1):27-30.
3. Blade J, Kyle RA. Nonsecretory myeloma, immunoglobulin D myeloma, and plasma cell leukemia. Haematol Oncol Clin North Am. 1999;13:1259-1272.
4. Kalra L, Delamere JP. Lymphoreticular malignancy and monoclonal gammopathy presenting as polymyalgia rheumatica. Br J rheumatol1987; 26: 458-9.
5. Franchi F, Seminara P, Teodori L, Adone G, Bianco P. The non-producer plasma cell myeloma. Report of a case and review of the literature. Blut. 1986 May;52(5):281-7.
6. D.R. Doster, J. Folds and d. A. Gabriel. Non secretory multiple myeloma, Archives of Pathology and Laboratory Medicine, vol.112, no. 2, pp 147-150,1988.
7. Devita V.T, Lawrence T.S, Rosenberg S. A. Cancer: Principles and practice of Oncology, 9th edition pg no. 2005-2008.
8. Harris E.D, Budd R.C, Firestein G.S. Kelleys textbook of Rheumatology 7th edition pg no. 1351.
9. Nothnagl T, Leeb BF. Diagnosis, differential diagnosis and treatment of polymyalgia rheumatica. Drugs Aging. 2006;23(5):391-402.