

Post-Transplant Renal Artery Stenosis needing Angioplasty

S Vasudevan, Amish Mehta, Vikas Kumar

a. Department of Urology, Government Medical College, Trivandrum*

ABSTRACT

Published on 26th March 2015

The causes of hypertension refractory to treatment in the post transplant scenario are commonly worsening renal function, renal artery narrowing and antibody mediated rejection. This may be insidious or obvious clinically on followup. It is a cause of considerable morbidity and occasional graft loss.

Nineteen year old female patient underwent related donor renal transplant and had a near normal post operative Doppler study of the renal vessels,

After 4-6 months she presented with headache and hypertension needing upto 4 drugs at a time (on Amlopress, Prazopress XL, Arkamine, Telvas) and with normal urea and creatinine levels. Colour Doppler Ultrasound was done which showed parvus tardus pattern suggestive of renal artery stenosis. CT Angiogram confirmed the narrowing of the renal artery segment. Transplant renal artery DSA demonstrated a tight stenosis just proximal to the arterial bifurcation and an Angioplasty done using a balloon mounted stent. Post operative results were excellent.

The case is reported to highlight the need for early detection, and prompt management to achieve excellent results.

Keywords: Hypertension, Post transplant recipient, Doppler USG, RAS, Angioplasty.

*See End Note for complete author details

INTRODUCTION

Hypertension poorly responding to medication in a post-transplant recipient is a matter of grave concern. Normally after a successful transplant glomerular filtration rate improves and the number of antihypertensive medication can be reduced. The causes of hypertension refractory to treatment in this scenario are commonly worsening renal function, renal artery narrowing and antibody mediated rejection. This may be insidious or obvious clinically on followup. It is a cause of considerable morbidity and occasional graft loss.

CASE PRESENTATION

A 19 year old female patient presented in April 2007 with headache, vomiting, blurring of vision, swollen face and leg edema and alopecia leading to a clinical diagnosis of Glomerulonephritis with uncontrolled hypertension. Initially she had normal urine output. Within 3 months she progressed to End Stage Renal Disease with peak serum creatinine levels 6.3 mg%. Renal biopsy proved IgA Nephropathy. She was initiated on haemodialysis and underwent 30 sessions of HD. Due to persisting hypertension she developed

hearing loss. She was considered for renal transplantation and underwent LRDT on 5th October 2009 with her mother donating and had a relatively uneventful surgery with conventional end to end anastomosis of renal artery to internal iliac artery. Warm ischemia time was 4 minutes and cold ischemia 60 minutes. Postoperative period was uneventful except for slight delayed graft function which normalised by 24-48 hours.

Colour Doppler performed on 1st postoperative day showed normal flow with mild reduction in lower pole vascularity. On postoperative day 14 an abrupt fall in urine output was observed with normal Doppler findings except for reduced lower pole PSV. The patient was discharged on 28th day with normal urine output, normal blood pressure and nadir creatinine level 1.2 mg%. Allograft biopsy on 35th day showed mild tubular injury. An episode of acute graft pyelonephritis with Klebsiella isolation and normal USG and renal functions (S Cr 1.2 mg%).

After 4-6 months she presented with headache and hypertension needing upto 4 drugs at a time (on Amlopress, Prazopress XL, Arkamine, Telvas) and with normal urea and creatinine levels. Immunosuppression was started routinely on postoperative day 1

Corresponding Author:

Dr. S Vasudevan, Additional Professor, Department of Urology, Government Medical College, Trivandrum.
E-mail: periamana@gmail.com

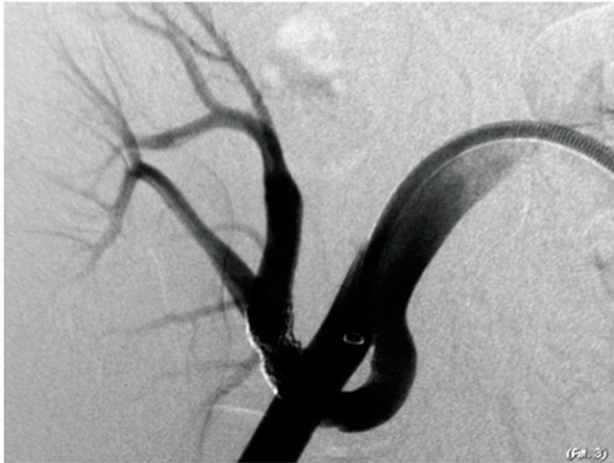

Figure 1. Angiogram showing narrow segment in post transplant renal artery

with 3 drugs (tacrolimus / MMF / steroids) with TAC levels at 2.3 mg% and 4.3 mg% on 7th Nov. and 8th Oct. respectively.

Colour Doppler Ultrasound was done on 25th October 2011 which showed parvus tardus pattern suggestive of renal artery stenosis. CT Angiogram on 31st October 2011 confirmed the narrowing of the renal artery segment. Transplant renal artery DSA done on 4th November 2011 demonstrated a tight stenosis just proximal to the arterial bifurcation and an Angioplasty done using a balloon mounted stent. The improvement in hypertension was observed within a few hours and now she needs only one drug. She has maintained the result since then with regular followup.

DISCUSSION

Transplant renal artery stenosis is the most common but potentially curable vascular complication in transplant patients.¹ The incidence varies from 1-23% in literature.² The wide range is mainly due to variable definition as well as improvement in peri-operative evaluations and techniques over time. The patient commonly presents with uncontrolled hypertension and deterioration in renal function which is unexplained.³ It usually occurs from 3 months to 2 years post-transplant⁴ but early or later presentations are not uncommon. Asymptomatic TRAS cases are progressively increasing as more use of non-invasive modalities like Colour Doppler Ultrasound and Magnetic Resonance Angiography.

Renal artery stenosis in transplant patient can be classified as 1. TRAS 2. Proximal or Pseudo TRAS. Proximal TRAS not only presents with renal dysfunction but also with buttock claudication and sometimes with lower limb claudication. TRAS can be sub classified according to the location of occurrence, including anastomotic stenosis, renal artery proper and segmental

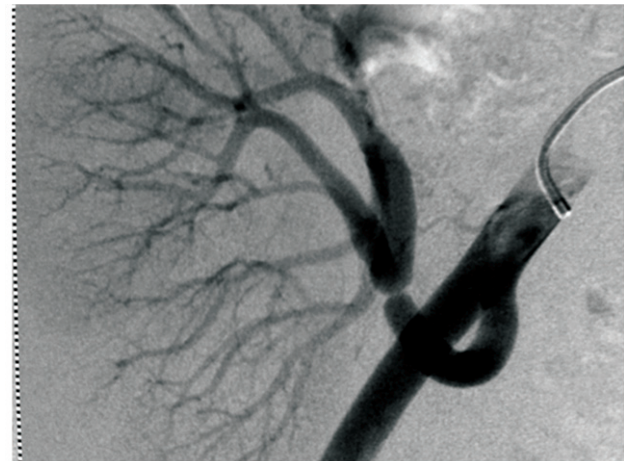


Figure 2. Showing renal artery dilated after PTA

renal artery stenosis. Several factors are responsible for TRAS mainly surgical clamp injury, intimal dissection, faulty suturing, external compression from fibrosis and kinking of long transplant arteries. Other predisposing factors are cyclosporine toxicity, CMV infection, cold ischemia time, acute cellular rejection etc.^{5,6} TRAS is more common in cadaveric donor kidney as well as end to end anastomosis. Pseudo TRAS means pre-existing or development of atherosclerotic inflow stenosis in the native iliac arteries (aorto-iliac atherosclerotic disease) of the transplant recipient. The incidence of pseudo TRAS has been reported up to 2.4% which may increase with age.^{5,7}

The sensitivity and specificity of Doppler USG is 87% to 94% and 86 to 100% respectively but operator dependent whereas MRA is ranging from 67% to 100% and 75% to 100% respectively.⁸ Doppler USG is well accepted screening tool for assessment of TRAS, as noninvasive and inexpensive. Important diagnostic parameters used to detect TRAS using DUS are peak systolic velocity, intra-renal dampening of flow and resistive index.⁹ Doppler parameters (peak systolic velocity [PSV] < 180 cm/s; resistive index [RI] > 0.50) and stable renal function invariably rule out TRAS and patient can be managed conservatively using anti-hypertensive therapy.¹⁰ Short acting ACE inhibitors can be used safely if serum creatinine and serum potassium level are normal. 6 monthly Doppler scan is advisable in patients on conservative management to detect early stenosis.

If BP is not controlled, unexplained worsening of renal function or non-invasive modalities are suggestive of progression of renal stenosis, diagnostic arteriography should be done and followed by angioplasty and stenting if indicated. Percutaneous Transluminal Renal Angioplasty can restore renal function in 70-90% of cases depending upon type of lesion.¹¹ Angioplasty and

stenting are preferred modality treatment for short and linear stenosis,¹² relatively distal to anastomosis.

Stenosis at anastomotic site is preferably treated by surgical approach as PTA alone has shown 10-33% recurrence over 6-8 months.¹³ In case of end to side anastomosis retrograde, ipsilateral femoral artery approach and in anastomosis to hypogastric artery, retrograde contralateral femoral artery puncture or brachial artery approach is preferred for renal artery angioplasty and stenting. With use of radioactive stents and stents releasing anti proliferative agents locally as enoxaparin and rapamycin can reduce the recurrence rate.^{14,15} Angioplasty with stenting is usually a safe procedure but complications have been reported in upto 10% of cases. Unusual complications as thrombosis, arterial dissection and rupture may occur in 4% of cases.

In cases with severe stenosis (>70%) or failed angioplasty, surgery is indicated. It includes resection and revision of anastomosis, patch graft, saphenous vein by-pass graft or end arterectomy. The success rate varies from 63-92% and recurrence is upto 12%.⁴ Though infrequently used, auto-transplantation of kidney is an important alternative in complex stenosis of graft arteries.

Doppler ultrasound is a non-invasive and reliable tool to monitor kidney perfusion.

CONCLUSION

In Renal transplant patients with severe or worsening of hypertension and unexplained renal dysfunction, TRAS should be suspected. Early detection is very important as it is a potentially treatable complication. In undiagnosed cases it results in graft loss and potentially fatal systemic complications. Full recovery of kidney perfusion with minimal risks can be achieved if diagnosed timely, improving graft survival.

END NOTE

Author Information

1. Dr. S Vasudevan, Additional Professor, Department of Urology, Government Medical College, Trivandrum
2. Dr. Amish Mehta, Senior Resident, Department of Urology, Government Medical College, Trivandrum
3. Dr. Vikas Kumar, Senior Resident, Department of Urology, Government Medical College, Trivandrum

Conflict of Interest: None declared

Editorial Comments:

Post transplant hypertension is a worrisome scenario. Non-invasive management of RAS is an option to be tried. This was the first case of our series.

Cite this article as: S Vasudevan, Amish Mehta, Vikas Kumar. Post-Transplant Renal Artery Stenosis needing Angioplasty. Kerala Medical Journal. 2015 Mar 26;8(1):28-30

REFERENCES

1. Luke RG, Curtis J. Biology and treatment of transplant hypertension. In: Hypertension Pathophysiology, Diagnosis and Management, edited by Laragh JH, Brenner BM, New York, Raven Press, 1995, pp 2471-2483
2. Fervenza FC, Lafayette RA, Alfrey EJ, Petersen J. Renal artery stenosis in kidney transplants. Am J Kidney Dis. 1998 Jan;31(1):142-8.
3. Ghazanfar A, Tavakoli A, Augustine T, Pararajasingam R, Riad H, Chalmers N. Management of transplant renal artery stenosis and its impact on long-term allograft survival: a single-centre experience. Nephrol Dial Transplant. 2011 Jan;26(1):336-43.
4. Roberts JP, Ascher NL, Fryd DS, Hunter DW, Dunn DL, Payne WD, Sutherland DE, Castaneda-Zuniga W, Najarian JS: Transplant renal artery stenosis. Transplantation 48: 580-583, 1989
5. Patel NH, Jindal RM, Wilkin T, Rose S, Johnson MS, Shah H, et al. Renal arterial stenosis in renal allografts: retrospective study of predisposing factors and outcome after percutaneous transluminal angioplasty. Radiology. 2001 Jun;219(3):663-7.
6. Humar A., Uknis M., Papaluis V., et al: Is there an association between cyto megalovirus and renal artery stenosis in kidney transplant recipients? Transplantation 2000; 69: pp.S386
7. Voiculescu A, Hollenbeck M, Plum J, Hetzel GR, Mödder U, Pfeiffer T, et al. Iliac artery stenosis proximal to a kidney transplant: clinical findings, duplex-sonographic criteria, treatment, and outcome. Transplantation. 2003 Jul 27;76(2):332-9.
8. Vasbinder GB, Nelemans PJ, Kessels AG, Kroon AA, de Leeuw PW, van Engelshoven JM. Diagnostic tests for renal artery stenosis in patients suspected of having renovascular hypertension: a meta-analysis. Ann Intern Med. 2001 Sep 18;135(6):401-11.
9. Goel MC, LaPerna L, Whitelaw S, Modlin CS, Flechner SM, Goldfarb DA. Current management of transplant renal artery stenosis: clinical utility of duplex Doppler ultrasonography. Urology. 2005 Jul;66(1):59-64.
10. O'Neill WC, Baumgarten DA. Ultrasonography in renal transplantation. Am J Kidney Dis. 2002 Apr;39(4):663-78.
11. Greenstein SM, Verstandig A, McLean GK, Dafoe DC, Burke DR, Meranze SG, et al. Percutaneous transluminal angioplasty. The procedure of choice in the hypertensive renal allograft recipient with renal artery stenosis. Transplantation. 1987 Jan;43(1):29-32.
12. Benoit G, Hiesse C, Icard P, Bensadoun H, Bellamy J, Charpentier B, Jardin A, Fries D: Treatment of renal artery stenosis after renal transplantation. Transplant Proc 19:3600-3601, 1987
13. Raynaud A, Bedrossian J, Remy P, Brisset JM, Angel CY, Gaux JC. Percutaneous transluminal angioplasty of renal transplant arterial stenoses. AJR Am J Roentgenol. 1986 Apr;146(4):853-7.
14. Kiesz RS, Buszman P, Martin JL, Deutsch E, Rozek MM, Gaszewska E, et al. Local delivery of enoxaparin to decrease restenosis after stenting: results of initial multicenter trial: Polish-American Local Lovenox NIR Assessment study (The POLONIA study). Circulation. 2001 Jan 2;103(1):26-31.
15. Waksman R, Ajani AE, White RL, Chan RC, Satler LF, Kent KM, et al. Intravascular gamma radiation for in-stent restenosis in saphenous-vein bypass grafts. N Engl J Med. 2002 Apr 18;346(16):1194-9.