

# Colpocephaly

M Sambasivan<sup>a</sup>, P Sanalkumar<sup>a</sup>, Abeed Basheer<sup>a</sup>

a. Cosmopolitan Hospital, Trivandrum\*

## ABSTRACT

Published on 27<sup>th</sup> June 2013

The authors report a rare case of Colpocephaly detected incidentally while investigating a case of Head trauma in a 6 year old boy. The C.T head revealed the typical picture of Colpocephaly with partial agenesis of Corpus Callosum.

**Keywords:** Colpocephaly, C.T. findings, Partial agenesis of Corpus Callosum

\*See End Note for complete author details

## INTRODUCTION

Colpocephaly is defined as disproportionate enlargement of occipital horns of lateral ventricles in association with partial or complete agenesis of Corpus Callosum. Approximately 36 cases have been described in children but antenatal diagnosis is infrequent. Here we report case of Colpocephaly with partial agenesis of Corpus Callosum - an incidental finding in a head injury patient

## CASE REPORT

A 6 year old boy was admitted in the Cosmopolitan hospital, Trivandrum with a history of alleged Road traffic Accident - hit by an auto rickshaw while crossing the road. The parents gave a history of initial loss of consciousness from which he recovered completely within 5 minutes. On admission to the hospital he complained of headache, pain and swelling occipital region.

On examination Patient was conscious, oriented, answering questions, pupils equal and reacting. Fundi - Normal. No focal neurological deficits. There was a small abrasion over the right frontal region and soft tissue contusion over the occipital region. No h/o Seizures, mental retardation, developmental delay or visual disturbances. BP 100/70, PR 78/mts. No Chest I Abdominal findings. He is the second child of a non consanguineous marriage. Normal full term delivery. The first child is alive and healthy.

C.T head was done to exclude Cranial/Intracranial injury.

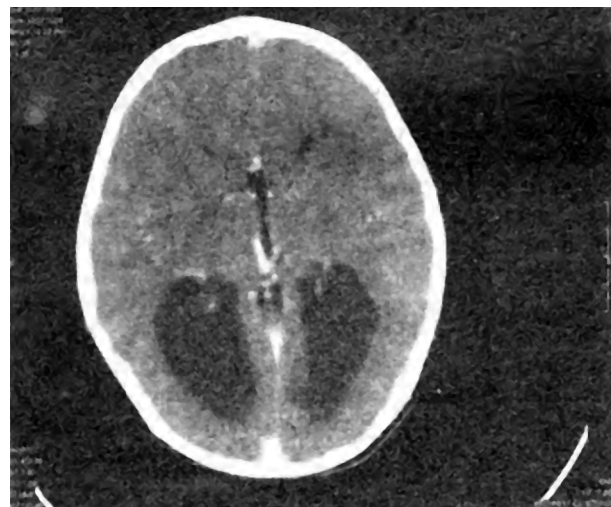


Figure 1. C.T. Head – Frontal horns of the Lateral ventricles appear small and splayed. Marked enlargement of the occipital horns of the Lateral ventricles. Highly placed 3rd Ventricle.

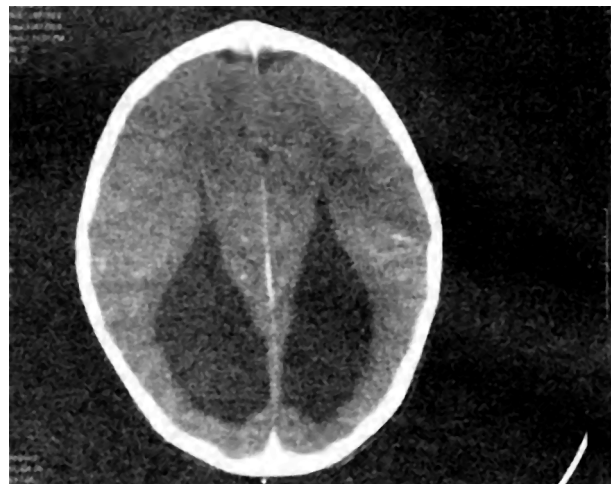

Figure 2. C.T. Head - Disproportionate enlargement of the occipital horns of the Lateral Ventricles. The Lateral ventricles. Highly placed 3rd Ventricle.

### Corresponding Author:

Dr. P Sanalkumar, M.S., MCh. Senior Consultant Neuro Surgeon, Cosmopolitan Hospital, Trivandrum.  
Phone: 9447393612. E-mail: imaksb@yahoo.co.in

### C.T. Head findings

Frontal horns of Lateral ventricles appear small and splayed. Highly placed Third ventricle which is not distended. Marked enlargement of the occipital horns of the Lateral ventricles. Cisterna magna prominent. No evidence of Intra Cranial injury. The C.T. picture was suggestive of Colpocephaly with partial agenesis of Corpus Callosum. Since there was no evidence of an increased Intracranial tension or Seizures or mental retardation he was managed conservatively.

### DISCUSSIONS

The term Colpocephaly was first introduced by Yakovlev, and Wadsworth. They stated that there is apparent dilatation of occipital horns and it represented a failure of development of cerebral wall with persistence of the embryonal vesicular character of the brain.

Most of the authors agree that the findings of colpocephaly include disproportionate enlargement of occipital horns with remaining ventricular system maintaining normal size and configuration. In addition most authors believe that the condition is associated with partial or complete agenesis of corpus callosum.

Various etiologies have been postulated including intrauterine or perinatal injuries, genetic disorders or an error of morphogenesis. Colpocephaly may also develop in later foetal life because of infarction and cystic degeneration of deep white matter of the posterior third of cerebral hemispheres rather than as a developmental disorder of neuroblast migration.

Colpocephaly is some times discovered late in pregnancy but is often misdiagnosed as Hydrocephalus. More often colpocephaly is diagnosed at birth when symptoms appear.

Of the 36 cases reported in the literature 13 patients had seizures, 12 patients were noted to have mental retardation. 13 of 36 cases were affected by mild to moderate movement disorders. Other reported deficits include poor vision, speech and language difficulties, deafness and chorio retinitis.

3 of the 36 cases reviewed had completely normal neurologic and motor development. Our case is an incidental one and belongs to this category.

There is no definitive treatment for colpocephaly. Anticonvulsant medication can be given to prevent seizures. They can participate in special education. Prognosis depends on the severity of brain malformation and other associated anomalies.

### END NOTE

#### Author Information

1. Dr. M Sambasivan, M.S., FRCS, Hon. Senior Consultant Neuro Surgeon, Cosmopolitan Hospital, Trivandrum
2. Dr. P Sanalkumar, M.S., MCh. Senior Consultant Neuro Surgeon, Cosmopolitan Hospital, Trivandrum
3. Dr. Abeer Basheer, MBBS, Medical Officer, Cosmopolitan Hospital, Trivandrum

**Conflict of Interest:** None declared

**Cite this article as:** M Sambasivan, P Sanalkumar, Abeer Basheer. Colpocephaly. Kerala Medical Journal. 2013 Jun 27;6(2):49-50

#### Acknowledgement

We are greatly indebted to directors and staff of Cosmopolitan Hospital for helping and allowing us to publish this material. We are thankful to Cosmopolitan Educational and Research Foundation for providing us with the material for researching this article. We are also thankful to Mr. M. Vijayachandran for his help in preparing the manuscript.

### REFERENCES

1. Garg. B.P: Colpocephaly, an error of morphogenesis?: Arch. Of Neurology – 39:243-246, 1982.
1. Herskowitz, Rosman.P, Wheeler.C.B. Calpocephaly: Neurology Clinical, radiologic and patho genetic aspects. 35: 1594-1598, 1985.