

Unusual Presentation of Primary Hyperparathyroidism in Type 2 Diabetes

Bilal Bin Abdullah^a, Syed Mustafa Ashraf^a, Md Zoheb^a, Sharafath Ali^a

a. Department of Medicine, Al Ameen Medical College, Bijapur, Karnataka*

ABSTRACT

Published on 28th December 2012

Here we report a 53 yr old diabetic female presenting with chronic pancreatitis, cholelithiasis. Initially, we thought her symptoms to be attributed in the background of chronic pancreatitis and Diabetes. Considering to her age, psychiatric manifestations, and no improvement in her clinical status, we investigated her parathyroid status. Finally we arrived to the diagnosis of parathyroid adenoma and she was operated, following which she improved dramatically.

A discrete evaluation confirmed the diagnosis of a parathyroid adenoma in a patient with type 2 diabetes, chronic pancreatitis, cholelithiasis, and neuropsychiatric manifestations.

Keywords: Diabetes mellitus, Primary hyperparathyroidism, Neuropsychiatric manifestations

*See End Note for complete author details

We report a 57 year old lady, known diabetic for last 4 years on OHA'S, attending Medical OPD of a tertiary medical care hospital with history of pain abdomen, nausea, loss of appetite since 3 months. on examination she was conscious well oriented, afebrile, with Pulse rate of 86/min, BP 130/84 mm hg, Respiratory rate 16/min, mild pallor, no icterus, she had right hypochondrium tenderness. Routine investigations revealed Hb 9.6 g%, fasting blood glucose 214 mg/dl and HbA1c 10.6%, normal serum amylase and lipase levels, urine for ketones was negative, all other investigations were within normal limits except for elevated serum alkaline phosphatase .Abdominal ultrasound showed multiple gall bladder stones. she was subjected for Endoscopic ultrasound which revealed a distended gall bladder containing multiple small calculi and a single large calculus; pancreas appeared bulky, parenchyma was hypoechoic with multiple hyperechoic areas with evidence of calcification, the impression was chronic pancreatitis, cholelithiasis. We further proceeded with ERCP.

ERCP showed CBD stones with left intra hepatic biliary dilatation with chronic calcific pancreatitis. For this she underwent endoscopic sphincterotomy and internal biliary stenting and was discharged with Tab pancreatin, H2 blockers and Inj Human mixtard of 30 units per day and she was asked to attend the opd after a fortnight.

After 1 week, she presented with symptoms of gastritis, insomnia, and mood disturbances. Upper GI endoscopy, showed Grade 1 distal oesophagitis, severe antral gastritis and duodenitis of D1 and D2, serum electrolytes and serum calcium were within normal range and she was managed conservatively and treated by psychiatrist for symptoms of depression with antidepressants Tab fluoxetine 20mgOD. Despite this there was no improvement. Owing to her age and symptoms we evaluated her parathyroid status.

Table 1. Lab Results

	Result	Reference range
Calcium Total	9.6 mg/dl	8.5-10.1 mg/dl
Ionised Calcium	5.8 mg/dl	4.5-5.6 mg/dl
PTH(intact)	903.7 pg/ml	14 - 72 pg/ml
Serum C-peptide		
Serum albumin		
Albumin corrected calcium	0.9 ng/ml	0.9-4.0 ng/ml
Corrected Calcium	3.4g/l	4-5 g/l
= (0.8 * (Normal Albumin - Pt's Albumin)) + Serum Ca	9.6mmol/l	

24 Hour urinary report

Total volume : 2200ml

Creatinine : 517mg/day (reference range 1–2 g/day)

Calcium : 158mg/day (reference range 80-200mg/day)

Phosphorous: 378mg/day (reference range upto 1g/day)

Corresponding Author:

Dr. Bilal Bin Abdullah, Professor and HOD, Department of Medicine, Al Ameen Medical College, Bijapur, Karnataka 586108.
Email: drbilal28@yahoo.com

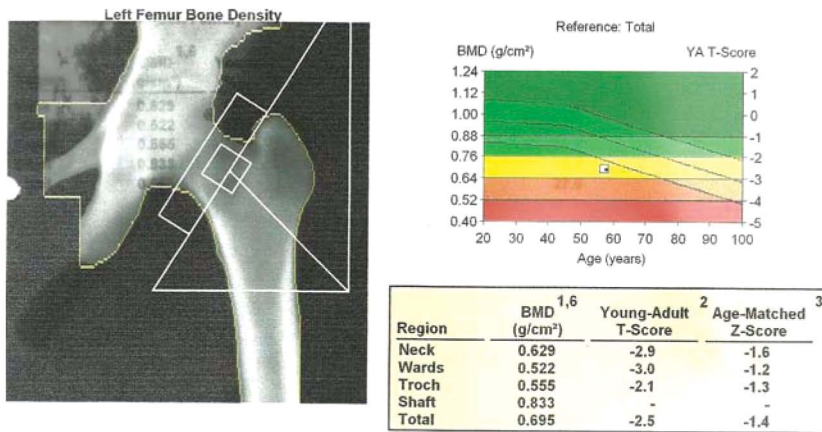


Figure 1. Femur Density of Left Bone

X-Rays of skull, spines were done: - Normal.

Parathyroid Scintigraphy with tracer Tc99m SESTAMIBI:

Early post injection and 1 hour images of anterior neck and anterior chest were obtained.

FINDINGS

Early images show tracer localized in the entire thyroid gland with large area of abnormally increased tracer uptake in the region of lower pole of right lobe of thyroid.

Delayed images show good washout of tracer from the thyroid gland with abnormal retention in the focus showing hyper concentration. No other focus of abnormal tracer retention detected elsewhere in the neck and mediastinum.

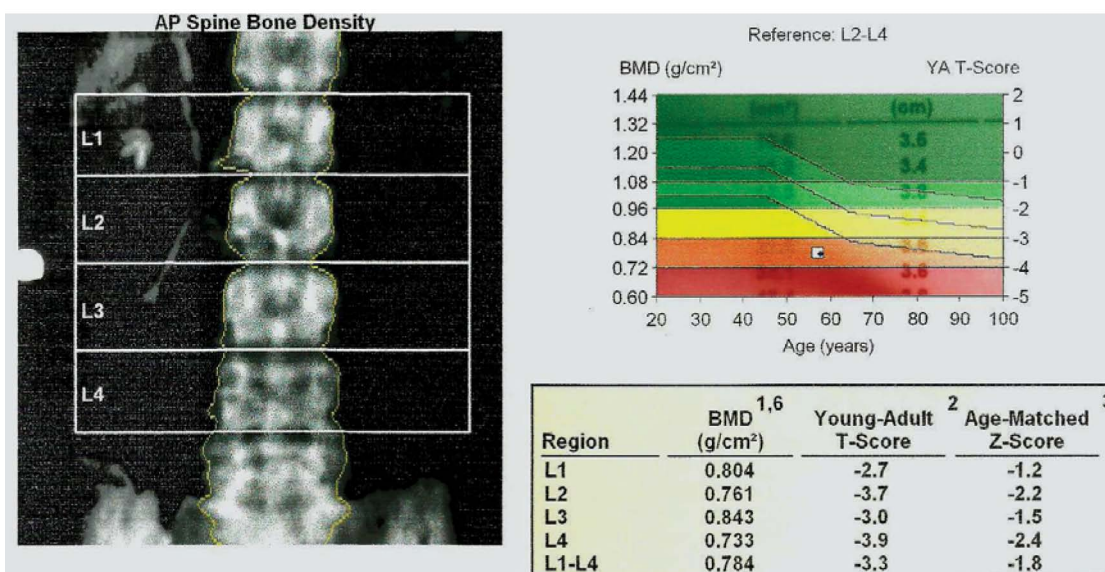
Impression: Scan findings are consistent with right parathyroid adenoma. She underwent right parathyroidectomy. Histopathology Report was consistent with PARATHYROID ADENOMA.

She is asymptomatic after then and improved, doing well with routine day to day activity. now, her fasting blood sugar was 133 mg/dL, Hb1AC- 7.8% and no other symptoms.

DISCUSSION

Here we report a 53 yr old diabetic female presenting with chronic pancreatitis, cholelithiasis. Initially, we thought her symptoms to be attributed in the background of chronic pancreatitis and Diabetes. Considering to her age, psychiatric manifestations, and no improvement in her clinical status, we investigated her parathyroid status. Finally we arrived to the diagnosis of parathyroid adenoma and she was operated, following which she improved dramatically.

Currently the prevalence rates of hyperparathyroidism are about 1 to 4 per 1000, with a female: male ratio of 3:1.¹ We evaluated bone density using DEXA scan which showed osteopenic changes. Most densitometry studies support the concept that the parathyroid hormone appears to be catabolic at cortical sites and may have anabolic effects at cancellous bone sites.² Hypercalcaemia is considered to be a rare cause of pancreatitis but the true cause-and-effect relation-



Comment:- Features suggestive of osteopenia

Figure 2. Bone density of Hip and Spine by DEXA

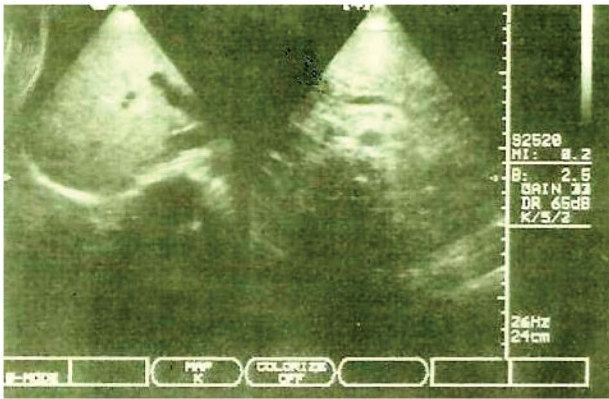


Figure 3. Ultrasound of liver and pancreas

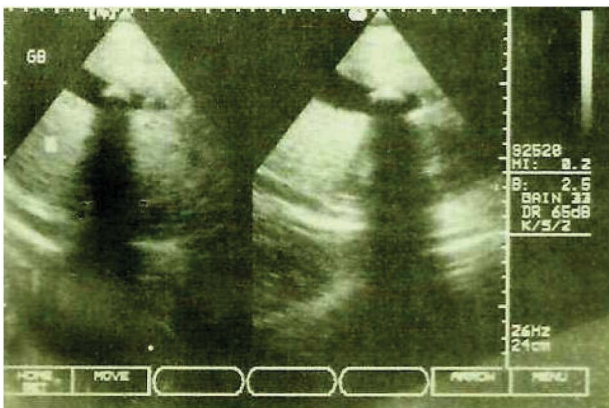


Figure 4. Ultrasound of Gall bladder

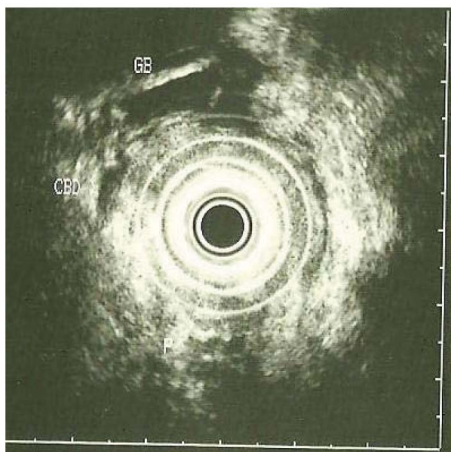


Figure 5. Endoscopic ultrasound

ship between hyperparathyroidism and pancreatic inflammatory disease remains controversial.³ Here the serum calcium, ionised calcium, albumin corrected calcium and urinary calcium levels were within normal limits, as such albumin corrected calcium has significance in albuminemic patients. Calcium and PTH levels vary inversely. Cope et al has reported that cholelithiasis is a common complication of hyperparathyroidism.⁴

Neuropsychiatric symptoms associated with primary hyperparathyroidism span a range of affective, anxiety, cognitive, and psychotic presentations. The

most common neuropsychiatric manifestations of the disorder appear to be depressive symptoms with general apathy and mild cognitive disturbance.⁵⁻⁶ There is increased incidence of type 2 DM in patients with hyperparathyroidism. Monica et al has reported the crude prevalence rate of type 2 DM in patients with primary hyperparathyroidism as 15.9%.⁷ Chronic recurrent pancreatitis with erosive gastritis is seen in patients with primary hyperparathyroidism.⁸ Despite her normal serum calcium levels, her PTH levels were elevated. A Swedish study has suggested incidence of 27.5 % of normocalcemic PHPT and 16% amongst post menopausal women.⁹

A discrete evaluation confirmed the diagnosis of a parathyroid adenoma in a patient with type 2 diabetes, chronic pancreatitis, cholelithiasis, and neuropsychiatric manifestations.

Bone density of Hip and Spine by DEXA

Comment: Features suggestive of osteopenia

Ultrasound of liver and pancreas

Ultrasound of Gall bladder

Endoscopic ultrasound

Histopathology Report

Clinical history: Tumour right parathyroid gland. To rule out malignancy.

Specimen: Resected Right Parathyroid gland

Macroscopic examination: Measurements: 4.2 x 2.8 x 2.3 cm

Weight: 8 gms

External surface: Greyish brown tissue, Capsule abraded in one area? Surgical

Cut surface: Tumour with fleshy appearance throughout

No. of bits: 2

Microscopic Examination: Sections studied shows an encapsulated tumour which consists of closely packed acini with scanty stroma in between.

The acini are lined by cuboidal to low columnar epithelium with round regular darkly stained nuclei with minimal variation. The cytoplasm is scanty to moderate and pale eosinophilic.

The capsule is thick, shows few trapped acini and plenty of pigment? hemosiderin laden macrophages.

There is no significant atypia or mitoses or necrosis.

There is no definite capsule or vascular invasion of surrounding structures.

Diagnosis: The histological features are consistent with Parathyroid adenoma.

END NOTE

Author Information

1. Dr. Bilal Bin Abdullah, Professor and HOD, Department of Medicine, Al Ameen Medical College, Bijapur, Karnataka 586108. Email: drbilal28@yahoo.com
2. Dr. Syed Mustafa Ashraf, Department of Medicine, Al Ameen Medical College, Bijapur, Karnataka
3. Dr. Md Zoheb, Department of Medicine, Al Ameen Medical College, Bijapur, Karnataka
4. Dr. Sharafath Ali, Department of Medicine, Al Ameen Medical College, Bijapur, Karnataka

Conflict of Interest: None declared

Cite this article as: Bilal Bin Abdullah, Syed Mustafa Ashraf, Md Zoheb, Sharafath Ali. Unusual Presentation of Primary Hyperparathyroidism in Type 2 Diabetes. Kerala Medical Journal. 2012 Dec 28;5(4):103-106

REFERENCES

1. Heath DA. Primary hyperparathyroidism. Clinical presentation and factors influencing clinical management. *Endocrinol Metab Clin North Am.* 1989 Sep;18(3):631–46.
2. Khan A. Primary hyperparathyroidism: diagnosis and management. *Endocr Pract.* 1997 Feb;3(1):22–6.
3. Sitges-Serra A, Alonso M, De Lecea C, Gores PF, Sutherland DER. Pancreatitis and hyperparathyroidism. *British Journal of Surgery.* 1988 Feb;75(2):158–60.
4. COPE et al O. Hyperparathyroidism: diagnosis and management. *Am J Surg.* 1960 Apr;99:394–40 and 3.
5. Geffken GR, Ward HE, Staab JP, Carmichael SL, Evans DL. Psychiatric morbidity in endocrine disorders. *Psychiatr Clin North Am.* 1998 Jun;21(2):473–89.
6. Spivak B, Radvan M, Ohring R, Weizman A. Primary hyperparathyroidism, psychiatric manifestations, diagnosis and management. *Psychother Psychosom.* 1989;51(1):38–44.
7. Cardenas M, Vigil K, Talpos G, Lee M, Peterson E, Rao D. Prevalence of Type 2 Diabetes Mellitus in Patients with Primary Hyperparathyroidism. *Endocrine Practice.* 2008 Jan 1;14(1):69–75.
8. Mendizova A, Baleva R, Zografski S, Dashev G. [Chronic recurrent pancreatitis with erosive gastritis in a patient with primary hyperparathyroidism]. *Vutr Boles.* 1976 Dec;15(6):76–8.
9. Lundgren E, Rastad J, Thruftell E, Akerström G, Ljunghall S. Population-based screening for primary hyperparathyroidism with serum calcium and parathyroid hormone values in menopausal women. *Surgery.* 1997 Mar;121(3):287–94.