

Two cases of Hereditary Nephritis

Sandeep U^a, Vasanth G^a, K Arul^a, Ganeshamoorthy^a, Ravikumar^a,
Isaac Christian Moses^a, A Prabhakaran^a, Veerakesary^a

a. Department of Pediatrics, Coimbatore Medical College Hospital, Coimbatore*

ABSTRACT

Published on 28th December 2012

ALPORTS SYNDROME is a rare inherited progressive form of glomerular disease with deafness and ocular abnormalities.¹ It is the second commonest genetic cause of renal failure. Thin basement membrane disease is thought to be underlying disease in 25% of patients with microscopic proteinuria.² We hereby report two cases of Alport's syndrome in siblings.

Two brothers of 18 & 23 years were admitted with complaints of decreased urine output, swelling of both legs of one month duration.

Keywords: Alport's syndrome, Hereditary nephritis

*See End Note for complete author details

INTRODUCTION

ALPORTS SYNDROME is a rare inherited progressive form of glomerular disease with deafness and ocular abnormalities.¹ It is the second commonest genetic cause of renal failure. Thin basement membrane disease is thought to be underlying disease in 25% of patients with microscopic proteinuria.² We hereby report two cases of Alport's syndrome in siblings.

CASE HISTORY

Two brothers of 18 & 23 years were admitted with complaints of decreased urine output, swelling of both legs of one month duration. There was no family history of any renal disease. On examination they were pale with features of volume overload. The elder brother had cataract in his right eye. The blood urea and creatinine was raised in both with an initial value of 29 in the elder brother and 11 in the younger brother. Both had hyperkalemia. There was 2+ albuminuria and hematuria in urine routine examination. Sonogram demonstrated contracted kidneys in both the siblings with increased cortical echoes and the corticomedullary differentiation was lost. Both of them had normocytic normochromic anaemia. All other investigations were normal including a retroviral testing, HbSAg, anti HCV and ANA.

Audiogram revealed bilateral moderate sensory neural hearing loss in both of the siblings. Slit lamp examination showed bilateral anterior lenticonus in

both of them with a cataract in right eye of the elder brother. They were taken to haemodialysis and fluid restriction. Renal biopsy was deferred because of having contracted kidneys in both of them.

DISCUSSION

Alport's syndrome is a hereditary, hematuric, non immune Glomerulonephritis that is characterised ultra structurally by progressive irregular thickening, thinning and lamellation of glomerular basement membrane and genetic mutation in COL4A3, COL4A4 or COL4A5 gene. It is associated with sensory neural hearing loss and other ocular findings. It has a

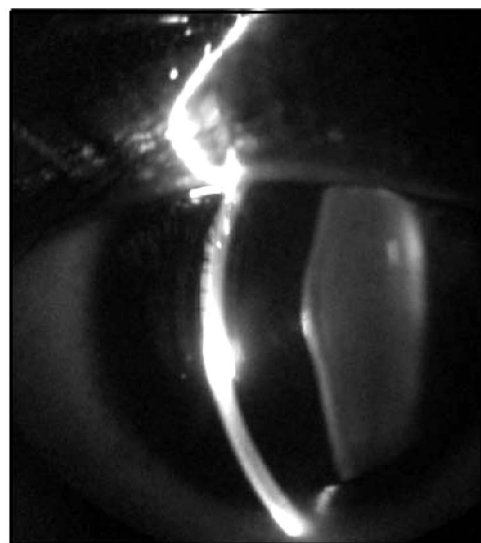


Figure 1. Anterior lenticonus

Corresponding Author:

Dr. Sandeep U, Department of Pediatrics, Coimbatore Medical College Hospital, Coimbatore.
E-mail: drsandeepu@gmail.com

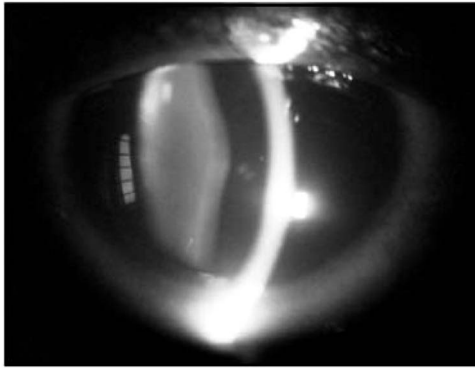


Figure 2. Anterior lenticonus

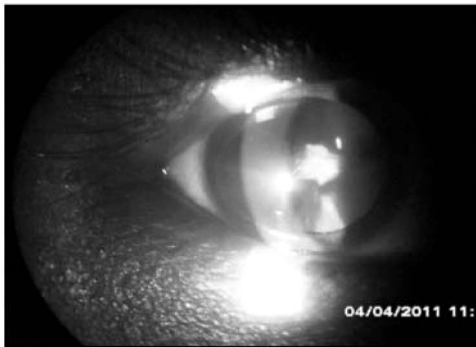


Figure 3. Cataract in Right eye

prevalence of 1 in 50000 live birth and accounts for 0.3 – 2.3 % of all end stage renal disease. Chronic hematuria is a cardinal sign of this disease. Type IV collagen composed of 3 alpha chains that form triple-helical structures through specific interactions of C-terminal non-collagenous domains. Six distinct IV collagen chains are encoded by six different genes distributed on three chromosomes.

- COL4A1 and COL4A2 at 13q34
- COL4A3 and COL4A4 at 2q35-37
- COL4A5 and COL4A6 on chromosome X

There are three modes of inheritance viz X-linked inheritance (80% cases).

Mutations in the COL4A5 gene on the X chromosome),³ AR (15% mutation in COL4A3 or COL4A4 genes), AD (5% due to mutation in COL4A3 or COL4A4 genes).⁴ Mutations impair their deposition into this collagen network, leading to secondary changes in GBM composition that predispose to the development of glomerulosclerosis. These chains are located in Bowman's capsule & basement membranes of the glomerulus, DCT, basement membranes of the cochlea & eye.⁵ The ocular findings include anterior lenticonus seen in 30% of X linked cases which is pathognomonic of Alport's syndrome.⁶ They also have sensory neural hearing loss due to impaired adhesion of organ of

Corti.⁷ Leiomyomas are also seen in some patients with X linked inheritance.

A diagnosis is made with clinical features, renal biopsy/skin biopsy and genetic testing. Renal transplantation is only treatment for definite cure, although anti GBM disease may occur in a minority. Angiotensin converting enzyme inhibitor and angiotensin receptor blockers can be given to delay the development of end stage renal disease. Cyclosporine has questionable role in management.⁹

In our case there was no family history of any renal disease. This probably reflects a denovo mutation in the genes in these two siblings making this interesting.

END NOTE

Author Information

1. Dr. Sandeep U, Department of Pediatrics, Coimbatore Medical College Hospital, Coimbatore
2. Dr. Vasanth G, Department of Pediatrics, Coimbatore Medical College Hospital, Coimbatore
3. Dr. K Arul, Department of Pediatrics, Coimbatore Medical College Hospital, Coimbatore
4. Dr. Ganeshamoorthy, Department of Pediatrics, Coimbatore Medical College Hospital, Coimbatore
5. Dr. Ravikumar, Department of Pediatrics, Coimbatore Medical College Hospital, Coimbatore
6. Dr. Isaac Christian Moses, Department of Pediatrics, Coimbatore Medical College Hospital, Coimbatore
7. Dr. A Prabhakaran, Department of Pediatrics, Coimbatore Medical College Hospital, Coimbatore
8. Dr. Veerakesary, Department of Pediatrics, Coimbatore Medical College Hospital, Coimbatore

Conflict of Interest: None declared

Cite this article as: Sandeep U, Vasanth G, K Arul, Ganeshamoorthy, Ravikumar, Isaac Christian Moses, A Prabhakaran, Veerakesary. Two cases of Hereditary Nephritis. Kerala Medical Journal. 2012 Dec 28;5(4):100-102

REFERENCES

1. Grunfeld J-P. Kidney International - Abstract of article: The clinical spectrum of hereditary nephritis. *Kidney Int.* 1985 Jan;27(1):83-92.
2. Williams EW, Turner AN. Glomerular basement membrane disorders and the kidney. *Medicine.* 2015 Sep 1;43(9):526-8.
3. Tryggvason K, Zhou J, Hostikka SL, Shows TB. Molecular genetics

- of Alport syndrome. *Kidney Int.* 1993 Jan;43(1):38–44.
4. Longo I, Porcedda P, Mari F, Giachino D, Meloni I, Deplano C, et al. COL4A3/COL4A4 mutations: from familial hematuria to autosomal-dominant or recessive Alport syndrome. *Kidney Int.* 2002 Jun;61(6):1947–56.
 5. Yoshioka K, Hino S, Takemura T, Maki S, Wieslander J, Takekoshi Y, et al. Type IV collagen alpha 5 chain. Normal distribution and abnormalities in X-linked Alport syndrome revealed by monoclonal antibody. *Am J Pathol.* 1994 May;144(5):986–96.
 6. Shaw EA, Colville D, Wang YY, Zhang KW, Dagher H, Fassett R, et al. Characterization of the peripheral retinopathy in X-linked and autosomal recessive Alport syndrome. *Nephrol Dial Transplant.* 2007 Jan;22(1):104–8.
 7. Merchant SN, Burgess BJ, Adams JC, Kashtan CE, Gregory MC, Santi PA, et al. Temporal bone histopathology in alport syndrome. *Laryngoscope.* 2004 Sep;114(9):1609–18.
 8. Cohen EP, Lemann J. In hereditary nephritis angiotensin-converting enzyme inhibition decreases proteinuria and may slow the rate of progression. *Am J Kidney Dis.* 1996 Feb;27(2):199–203.
 9. Callís L, Vila A, Carrera M, Nieto J. Long-term effects of cyclosporine A in Alport's syndrome. *Kidney Int.* 1999 Mar;55(3):1051–6.