

# Two cases of Hypokalemic Paralysis due to Distal Renal Tubular Acidosis

Anoop John<sup>a</sup>, Santhosh Kumar S P<sup>a</sup>, Rojith K B<sup>a</sup>, D K Sivakumar<sup>a</sup>,  
T Geetha<sup>a</sup>, S Avudiappan<sup>a</sup>, Isaac Christian Moses<sup>a</sup>, S Usha<sup>a</sup>

a. Department of General Medicine, Coimbatore Medical College, Coimbatore\*

## ABSTRACT

Published on 27<sup>th</sup> September 2012

Hypokalemic periodic paralysis is a rare disorder characterized by transient attacks of flaccid paralysis of varying intensity and frequency. Although mostly familial in etiology, several sporadic cases have been reported, including some resulting from renal tubular acidosis. Here we present two cases, first of a 55 yr. old woman with recurrent attacks of flaccid paralysis, and the second, of a 16 yr. Old girl who presented with flaccid quadriplegia with no similar history in the past, both of whom on evaluation turned out to be secondary hypokalemic periodic paralysis caused by Distal Renal Tubular Acidosis (RTA). As the clinical appearance of hypokalemic paralysis distal RTA is quite similar to Familial Hypokalemic Periodic Paralysis (FPP), and because the emergent and prophylactic treatment of the two disorders is quite different, we discuss the diagnostic evaluation and the treatment of distal renal tubular acidosis.

**Keywords:** Paralysis, Acidosis, Hypokalemia, Renal tubular acidosis, Hypokalemic periodic paralysis

\*See End Note for complete author details

## CLINICAL DETAILS

### Case 1

#### History

A 55-year-old woman came to the hospital due to a 24-hour weakness of all four limbs. She reported having had similar episodes 5 times previously, most recently 4 months ago; on those occasions, parenteral administration of fluids improved her condition over

3-5 days. She was not able to reproduce any of the old records regarding her treatment. Resting after exercise or eating did not precipitate the weakness, and there was no family history of similar illness. She reported no sensory involvement and no bladder or bowel involvement and had no history of fever, cough, or any recent illness.

#### Physical Examination

On examination, she was alert, awake, and oriented. Vital signs were stable. Lungs were clear to auscultation, and abdominal examination revealed no abnormalities. Cranial nerves were all intact. The patient had hypotonic weakness in all four limbs (grade 3/5 power) and generalized hyporeflexia. Plantar reflexes were

normal, and there was no sensory deficit.

#### Laboratory Evaluation

Laboratory examination revealed severe hypokalemia (1.6mEq/L) with metabolic acidosis (pH of 7.31). Anion gap was normal. Blood urea, serum creatinine, and uric acid levels were within normal limits. Thyroid profile was normal. ECG at admission revealed sinus bradycardia and U waves. A thorough work up regarding the cause of her recurrent hypokalemia was carried out.

The 24hr K<sup>+</sup> excretion was 48mmol/day and the trans tubular potassium gradient (TTKG) was 18.14. Urine was alkaline with a pH of 7.1 (fresh morning sample) for 3 consecutive days. Ultrasound abdomen did not reveal nephrocalcinosis. The diagnosis of distal RTA was made by the findings of systemic acidosis, hypokalemia, a normal anion gap and alkaline urine despite the acidaemia.

Patient was started on oral potassium citrate 3g/day and power improved over the next two days. Serum electrolytes on discharge were within normal limits (K<sup>+</sup>-4.0mEq/L). Patient is on regular follow up and remains asymptomatic.

#### Corresponding Author:

Dr. Anoop John, Junior Resident, Department of General Medicine, Coimbatore Medical College, Coimbatore.  
Phone: 08870782563. E-mail: johny316@gmail.com

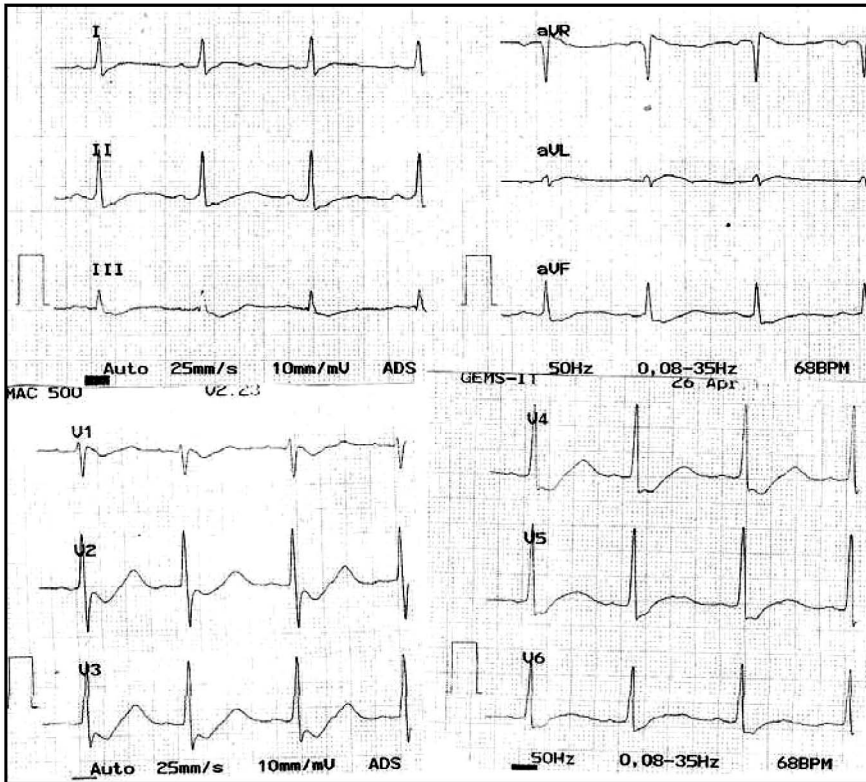


Figure 1. ECG showed prolonged QT interval and ST segment depression

**Case 2**

**History**

A 16-year-old girl presented to our hospital with weakness of all four limbs of 1 day duration. She had no similar episodes prior to admission. Resting after exercise or eating did not precipitate the weakness, and there was no family history of similar illness. She reported no sensory involvement and no bladder or bowel involvement and had no history of fever, cough, or any recent illness.

**Physical Examination**

On examination, she was alert, awake, and oriented. Vital signs were stable. Lungs were clear to auscultation, and abdominal examination revealed no abnormalities. Cranial nerves were all intact. The patient had hypotonic weakness in all four limbs (grade 2/5 power) and generalized hyporeflexia. Plantar reflexes were normal, and there was no sensory deficit.

**Laboratory Evaluation**

Laboratory examination revealed severe hypokalemia (1.8 mEq/L) with metabolic acidosis (pH of 7.33). Anion gap was normal. Blood urea, serum creatinine, and uric acid levels were within normal limits. Thyroid profile was normal. ECG at admission revealed prolonged QT interval with ST segment depression.

The following is the ECG.

A thorough work up regarding the cause of her recurrent hypokalemia was carried out. The 24hr K<sup>+</sup> excretion was 25.8mmol/day and the trans tubular potassium gradient (TTKG) was 7.07. Urine was alkaline with a pH of 8.0 (fresh morning sample) for 3 consecutive days. Ultrasound abdomen did not reveal nephrocalcinosis. The diagnosis of distal RTA was made by the findings of systemic acidosis, hypokalemia, a normal anion gap and alkaline urine despite the acidaemia.

Patient was started on oral potassium citrate 2.5g/day and power improved completely over the next four days. Serum electrolytes on discharge were within normal limits (K<sup>+</sup> - 4.2mEq/L). Patient was on regular follow

up and remained asymptomatic for over 7 months, but then was non adherent to the treatment and was admitted with another episode of hypokalemic paralysis, which recovered completely in 3 days after restarting the patient on oral potassium citrate.

**DISCUSSION**

Acute hypokalemic periodic paralysis (HPP) is a relatively uncommon, potentially fatal condition if untreated and completely reversible with appropriate management. Ascending paralysis is likely to occur at serum potassium level of 2-2.5 meq/l. Besides potassium replacement therapy the approach to a patient with HPP includes a thorough evaluation to find out the underlying cause of hypokalaemia. The usual causes of hypokalemic periodic paralysis include familial periodic paralysis (FPP), thyrotoxicosis, distal RTA, hyperaldosteronism, gastrointestinal loss and barium poisoning.<sup>1</sup>

Episodic weakness with onset after age 25 is almost never due to familial periodic paralysis with the exception of thyrotoxic periodic paralysis.<sup>2</sup> A systematic approach to hypokalemia can lead to an early diagnosis and avoid unnecessary investigations. A similar approach was adopted here as shown in the following table.<sup>3</sup>

Distal RTA is a clinical syndrome consisting of a

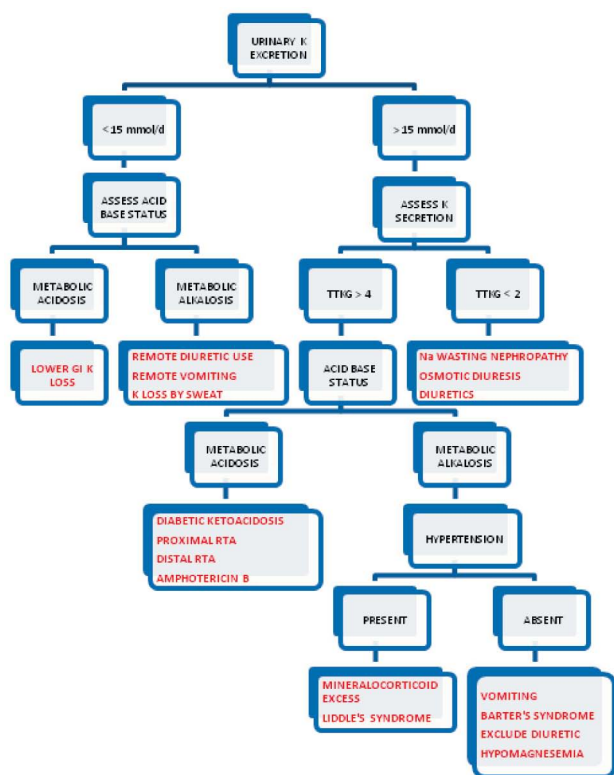


Figure 2. Systematic approach to diagnosis the cause of hypokalemia

hypokalaemia, hyperchloaemic metabolic acidosis with normal anion gap, inability to lower urinary pH below 5.5, nephrocalcinosis, osteomalacia or rickets. The basic defect is impairment of H<sup>+</sup>- K<sup>+</sup> ATPase proton pump; failure of this pump leads to defect in acidification and urinary potassium loss with all the features of distal RTA.<sup>4</sup> Primary distal RTA is inherited in an autosomal dominant fashion but most cases are sporadic. Rarely distal RTA occurs in autosomal recessive forms. Secondary causes of distal RTA are Sjogren's syndrome, use of amphotericin B, and certain blood disorders like sickle cell anaemia.<sup>5</sup> Treatment of distal RTA requires alkali administration (equivalent to the sum of endogenous acid production and amount of accompanying bicarbonate wastage) in the form of Shohl's solution, which is a combination of sodium citrate and citric acid. The usual dose of Shohl's solution is 0.5-2.0 mmol/kg bodyweight in 4-6 divided doses per day.<sup>6</sup> Maintenance of alkali therapy for an indefinite period is necessary. Potassium alkali salts can be used if hypokalemia is a persistent problem. Citrate requires less frequent dosing than bicarbonate salts as it is metabolized to bicarbonate after absorption. K<sup>+</sup> supplementation may be given in few patients at 2 to 4 mEq/kg/day. This can also be given as modified Shohl's solution containing Na<sup>+</sup> and K<sup>+</sup> citrate to treat both acidosis and hypokalemia.

It is essential to differentiate between HPP due to RTA and FPP as the emergency treatment and prophylaxis differ. Bicarbonate is contraindicated in FPP as it facilitates intracellular potassium influx and fatal hypokalemia may result. Combination of acetazolamide and potassium affords a good level of prophylaxis in FPP. Potassium-sparing diuretics like triamterene (25-100 mg/d) and spironolactone (25-100 mg/d) are second-line drugs to be used in patients in whom the weakness worsens, or in those who do not respond to carbonic anhydrase inhibitors. As these diuretics are potassium sparing, potassium supplements may not be necessary. However, acetazolamide is strongly contraindicated in prophylaxis of distal RTA because it can increase the metabolic acidosis.<sup>7</sup>

## END NOTE

### Author Information

1. Dr. Anoop John, Junior Resident, Department of General Medicine, Coimbatore Medical College, Coimbatore. E-mail: johny316@gmail.com Phone: 08870782563
2. Dr. Santhosh Kumar S P, Junior Resident, Department of General Medicine, Coimbatore Medical College, Coimbatore.
3. Dr. Rojith K B, Junior Resident, Department of General Medicine, Coimbatore Medical College, Coimbatore.
4. Dr. D K Sivakumar, Junior Resident, Department of General Medicine, Coimbatore Medical College, Coimbatore.
5. Dr. T Geetha, MD, Associate Professor, Department of General Medicine, Coimbatore Medical College, Coimbatore.
6. Dr. S Avudiappan, MD, Associate Professor, Department of General Medicine, Coimbatore Medical College, Coimbatore.
7. Dr. Isaac Christian Moses, MD, Professor, Department of General Medicine, Coimbatore Medical College, Coimbatore.
8. Dr. S Usha, MD, Professor, Department of General Medicine, Coimbatore Medical College, Coimbatore.

**Conflict of Interest:** None declared

**Cite this article as:** Anoop John, Santhosh Kumar SP, Rojith KB, DK Sivakumar, T Geetha, S Avudiappan, Isaac Christian Moses, S Usha. Two cases of Hypokalemic Paralysis due to Distal Renal Tubular Acidosis. Kerala Medical Journal. 2012 Sep 27;5(3):75-78

## REFERENCES

1. Ahlawat SK, Sachdev A. Hypokalaemic paralysis. Postgrad Med J. 1999 Apr 1;75(882):193-7.
2. Brown RH, Jr., Amato AA, Mendell JR. Muscular dystrophies and other muscle diseases. In : Kasper DL, Braunwald E, Fauci AS, et al, ed. Harrison's Principles of Internal Medicine.17th ed. NewYork:McGraw Hill 2008: 2678-95.
3. Singer GG, Brenner BM. Fluid and electrolyte disturbances. In: Kasper DL, Braunwald E, Fauci AS, et al, ed. Harrison's Principles of Internal Medicine.17th ed. New York: McGraw Hill 2008: 274-85.
4. Agarwal AK, Wadhwa S, Sood VR. Primary hypokalaemic periodic paralysis--a further experience. J Assoc Physicians India. 1993 Nov;41(11):760.
5. Soriano JR. Renal Tubular Acidosis: The Clinical Entity. JASN. 2002 Aug 1;13(8):2160-70.
6. Aspin JR, Coe FL. Tubular disorders. In : Kasper DL, Braunwald E, Fauci AS, et al, ed. Harrison's Principles of Internal Medicine.16thed.NewYork:McGraw Hill20 05:1694-702.
7. Koul PA, Saleem SM, Bhat D. Sporadic distal renal tubular acidosis and periodic hypokalaemic paralysis in Kashmir. J Intern Med. 1993 Jun;233(6):463-6.