

Unusually Large Myositis Ossificans of Elbow

Shyam Roy A S^a, B P Vinod Kumar^a, Mohammed Sageer^a, Raffic M^a

a. Department of Orthopaedics, Government Medical College, Thiruvananthapuram*

ABSTRACT

Published on 28th June 2012

An eighteen year old male came to our out-patient department with contusion right elbow with moderate edema and tenderness. X-rays showed no evidence of fracture. He was treated with above elbow POP slab in 90 degree flexion. He was lost for follow up and presented 6 weeks later with a swelling in the anterior aspect of arm and inability to flex the elbow to full range. He had massage after removing the plaster. On examination flexion was possible only upto 45 degree and a bony hard, non tender, large non mobile mass was palpated over anterior aspect of arm. Roentgenographic examination showed an anterior myositis ossificans of 6 x 4 cms in brachialis. He was treated conservatively with indomethacin, isometric muscle strengthening and gentle active assisted range of muscle exercises within the limits of pain. Range of motion progressively increased over a period of 2 months, and he could improve his range to 110 degree. By another 2 months he was able to completely restore the mobility, the size of the myositis mass decreased.

Keywords: Contusion, Massage, Anterior myositis ossificans, Isometric muscle exercises

*See End Note for complete author details

Myositis ossificans most commonly occurs following trauma to musculoskeletal system. Patients usually presents with swelling, pain and a decreased range of motion. But a myositis mass of 6 cms is unusual and rare. More than one-half of the patients have a history of injury and with a history of passive movements of involved joints especially elbow and knee and massage. It can also occur without any identifiable fractures. Von Dusch was first to suggest the term myositis ossificans in 1868. Myositis ossificans is a misleading term; lesion is not inflammatory and an origin in the muscle is not a prerequisite for the diagnosis (Ackennan 1958).¹ New bone formed in myositis lacks periostium and it do not follow anatomical planes. Certain occupations and sports are reported to have an increased chance of myositis ossificans in particular areas. Brachialis in fencers, adductor longus in horse riders (Prussian disease), deltoid in soldiers, solieus in dancers and quadriceps in foot ball players are common due to repeated trauma. In most cases lesion is not attached to the underlying bone, but it can be attached if it lies near the bone and the original injury induced adjacent periosteal reaction. Initially the radiograph shows only faint, irregular, floccular radiodensities (some times called dotted-veil pattern; Enzinger et al).³ As the lesion mature, the radiographic appearance changes to that of bone formation, characteristically beginning at the periphery of the lesion. The center of the lesion remains radiolucent,

a characteristic that can be demonstrated by CT scan. Serial radiographic studies done over a period of years will show the volume of myositic mass to decrease gradually. Classically 4 zones can be demonstrated in mid osseus phase of the myositic mass (2-6 wks).¹ Inner most layer consist of highly active cells with mitotic figures, adjacent layer of cellular osteoid, zone of new bone formation with trabacular organization and the peripheral zone of fibrous tissue formation (Ackerman et al).¹ Although the use of aspiration biopsy for cytological diagnosis has been reported, does not allow to view the cross section of the lesion and there by document the zone phenomenon (Aisner et al).² When a biopsy of the lesion is warranted, a large sample of tissue that preserves the architecture of the mass is essential for the accurate diagnosis (Mina et al).⁴ Manipulation should be avoided.⁷ Since the diagnosis could be established with a proper history and imaging studies, an exision is seldom necessary.⁷ Pharmacological agents used to inhibit heterotopic ossification have disadvantage of causing side effects; both diphosphonates and NSAIDs can interfere with fracture healing, and the former, when used for prolonged periods of as long as six months as suggested can result in osteomalacia.⁸ Radiation therapy is the only local measure available for the prevention and treatment of myositis.⁸ The timing of resection of myositis mass remains controversial because of the risk of recurrent ossification. Failla et al after a review of

Corresponding Author:

Dr. B P Vinod Kumar, Assistant Professor, Department of Orthopaedics, Government Medical College, Thiruvananthapuram.
Phone: 9847279516. E-mail: imaksb@yahoo.co.in

the experience with 20 patients over a 42 year period, recommended that operative resection can be delayed for 12 months after the injury but be performed within 3 years.⁹ Myositis mass is considered mature when serial radiograph demonstrate that the extent of the mass is not increasing, that the margin between the heterotopic bone and the soft tissue is distinct.

UNUSUALLY LARGE MYOSITIS OSSIFICANS

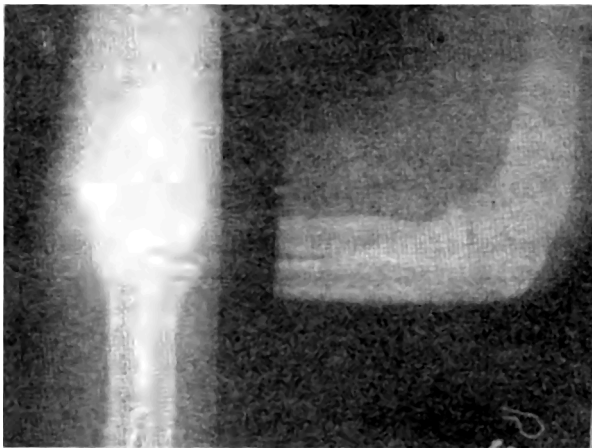


Figure 1. Contusion@ Elbow

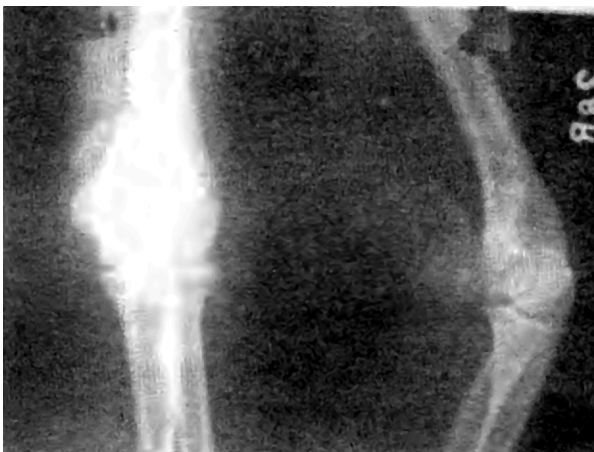

Figure 2. Unusual large anterior myositis 6 weeks

END NOTE

Author Information

1. Dr. Shyam Roy A S, Resident, Department of Orthopaedics, Government Medical College, Thiruvananthapuram
2. Dr. B P Vinod Kumar, Assistant Professor, Department of Orthopaedics, Government Medical College, Thiruvananthapuram
3. Dr. Mohammed Sageer, Senior Lecturer,

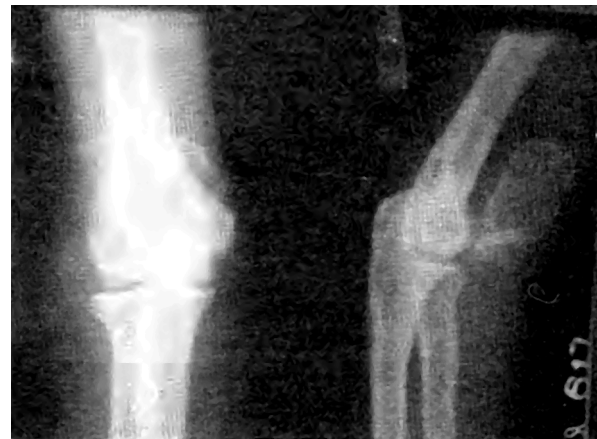

Figure 3 Unusual Large anterior myositis 10 weeks

Department of Orthopaedics, Government Medical College, Thiruvananthapuram

4. Dr. Raffic M, Professor, Department of Orthopaedics, Government Medical College, Thiruvananthapuram

Conflict of Interest: None declared

Cite this article as: Shyam Roy A S, B P Vinod Kumar, Mohammed Sageer, Raffic M. Unusually Large Myositis Ossificans of Elbow. Kerala Medical Journal. 2012 Jun 28;5(2): 49-50

REFERENCES

1. Ackerman LV. Extra-osseous localized non-neoplastic bone and cartilage formation (so-called myositis ossificans): clinical and pathological confusion with malignant neoplasms. *J Bone Joint Surg Am.* 1958 Apr;40-A(2):279-98.
2. Aisner SC, Burke KC, Resnik CS. Aspiration cytology of heterotopic ossification. A case report. *Acta Cytol.* 1992 Apr;36(2):159-62.
3. Enzinger F.M. & Weiss .S.W soft tissue tumors; : pp.1.5-7 St. Louis C.V. Mosby 1983
4. Mirra J.M; Picci.P & Gold R.H; Bone Tumors; clinical, radiological and pathological correlation. pp: 1550-1575, Philadelphia; Lea & Febiger 1989.
5. Rockwood and Wilkins:Tames.H.Beaty. M.D & James R Kasser :M.D. Fractures in children, 5: 724-726, 2001
6. Rockwood and Greens : Robert W Buchal:: M.D & James D Heckman M.D. Vol 1, fractures in adults, 5: 929-931, 2001
7. Instructional course lectures; The American academy of orthopaedic surgeons - evaluation diagnosis & classification of benign soft tissue tumors. Jan 1996, vol 78A. no:1
8. McAuliffe JA, Wolfson AH. Early excision of heterotopic ossification about the elbow followed by radiation therapy. *J Bone Joint Surg Am.* 1997 May;79(5):749-55.
9. Failla JM, Amadio PC, Morrey BF. Post-traumatic proximal radio-ulnar synostosis. Results of surgical treatment. *J Bone Joint Surg Am.* 1989 Sep;71(8):1208-13.