

# Extralobar and Intralobar Pulmonary Sequestrations - Report of 4 Cases

C P Rauf<sup>a</sup>, Sangeetha E<sup>b</sup>, Deepak Kumar R<sup>b</sup>, Deepti Krishnan<sup>b</sup>, M Umar Majid<sup>b</sup>

a. Indian Medical Association, Anayara PO, Trivandrum; b. Chest Hospital, Pavamani Road, Calicut\*

## ABSTRACT

Published on 30<sup>th</sup> March 2012

It is important to keep in mind Pulmonary sequestration when a patient presents with bronchiectasis or haemoptysis.

Sequestration occurs in two forms, the extralobar and the intralobar types. There is a partial or complete separation of part of a lung from the normal connection with the bronchial tree. The arterial blood supply to this region most often arises from the aorta above or below the diaphragm. No pulmonary artery branch is found in the involved segments.

Diagnosis is usually made during investigations for haemoptysis,<sup>2</sup> bronchiectasis, or while patient is being taken up for bronchial artery embolisation therapy for massive haemoptysis or during pulmonary resection for bronchiectasis when surgeon finds a systemic arterial supply to the region. The gross appearance is that of nonaerated lung parenchyma resembling liver tissue. Intralobar sequestrations occur about six times as often as extralobar sequestrations. They usually are located in the dorsal segments of the lower lobes. The blood supply comes from the aorta through one or several anomalous arteries, usually originating in the descending aorta or in the aorta below the diaphragm, but it has also been observed arising from intercostals or in nominate artery. Venous drainage is toward the normal pulmonary veins.

We are presenting four cases of Pulmonary Sequestrations. Among four cases two intralobar (one on right side and one on left side). Two extralobar one an right side and one on left side. The clinical and radiological findings are presented.

**Keywords:** Pulmonary sequestration, Haemoptysis, Bronchiectasis

\*See End Note for complete author details

We are presenting four cases of Pulmonary Sequestrations. Among four cases two intralobar (one on right side and one on left side). Two extralobar one an right side and one on left side. The importance of keeping in mind the possibility of sequestration when a patient presents with bronchiectasis or haemoptysis is highlighted.

Sequestration occurs in two forms, the extralobar and the intralobar types. There is a partial or complete separation of part of a lung from the normal connection with the bronchial tree. The arterial blood supply to this region most often arises from the aorta above or below the diaphragm. No pulmonary artery branch is found in the involved segments. In extralobar sequestrations, the parenchyma has a separate pleural covering the anomalous artery usually comes from below the diaphragm and the anomalous veins drain into the (hemi) azygos vein or into the portal system. Most extralobar sequestrations are located in the left costodiaphragmatic recess. They are found below the diaphragm also.<sup>1</sup>

Diagnosis is usually made during investigations for

haemoptysis,<sup>2</sup> bronchiectasis, or while patient is being taken up for bronchial artery embolisation therapy for massive haemoptysis or during pulmonary resection for bronchiectasis when surgeon finds a systemic arterial supply to the region. The gross appearance is that of nonaerated lung parenchyma resembling liver tissue. Intralobar sequestrations occur about six times as often as extralobar sequestrations. They usually are located in the dorsal segments of the lower lobes. The

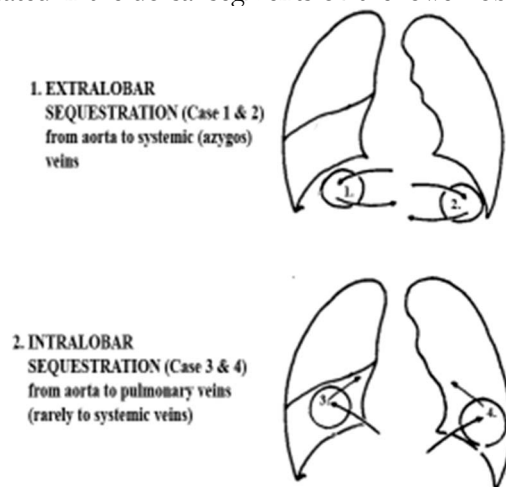


Figure 1. Sites of sequestration in our series

### Corresponding Author:

Dr. C P Rauf, Consultant Pulmonologist, Chest Hospital, Pavamani Road, Calicut – 673004.  
E-mail: drauffcp@bsnl.in

blood supply comes from the aorta through one or several anomalous arteries, usually originating in the descending aorta or in the aorta below the diaphragm, but it has also been observed arising from intercostals or in norninate artery. Venous drainage is toward the normal pulmonary veins.<sup>3</sup>

**Case 1**

Mrs. P 85Yrs presented to us with massive haemoptysis. She gives history of similar episodes at variable interval for the last 20 yrs. Physical examination showed no digital clubbing and there were crepitations in the right mammary area. X ray Chest P. A view showed patchy area of consolidation in right mid and lower zone.

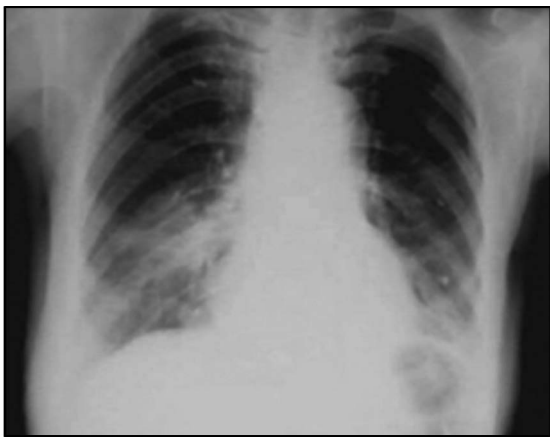


Figure 2. X-ray Chest P. A View : Patchy area of consolidation in right mid and lower zone

Fiberoptic bronchoscopy showed bleeding from middle lobe bronchus. CT thorax showed a contrast enhancing lesion in the middle lobe.

Aortogram was done which showed a large vessel supplying the area in the middle lobe. There was rapid entry of contrast to the left atrium and hence bronchial arterial embolisation therapy was not done.

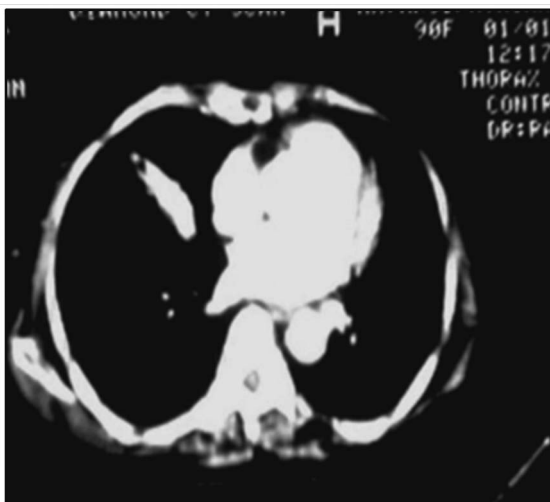


Figure 3. CT Thorax showed contrast enhancing lesion in the middle lobe

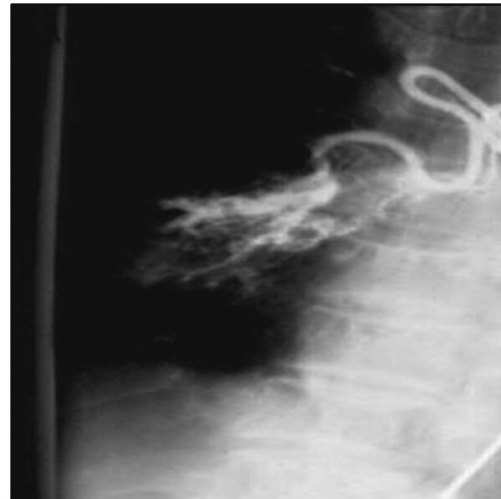

Figure 4. Aortogram showing a large vessel supplying in the middle lobe

She was advised surgical treatment which she refused. This case has typical features of intralobar sequestration.

**Case 2**

Mr. S. 22Yrs presented to us with history of recurrent episodes of haemoptysis often 10-20 ml almost every one to two months for the last 10yrs. His X ray Chest P.A View was normal. His CT Scan showed increased vascular markings in the left lower lobe

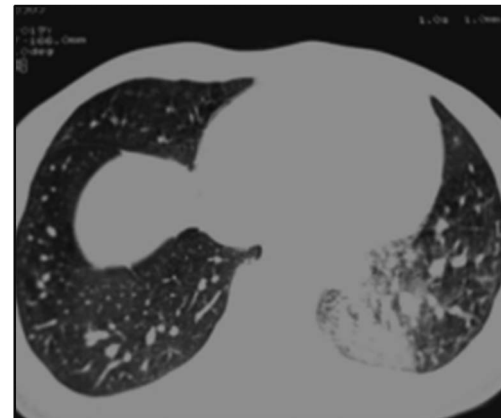


Figure 5. CT showed increased vascular markings in the left

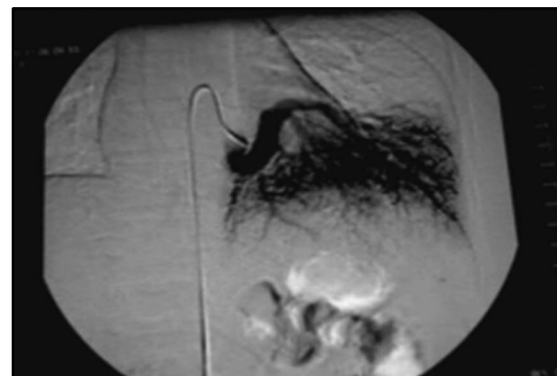


Figure 6. Aortogram showed large vessel arising from the aorta supplying the left lower lobe

His aortogram showed large vessel arising from the aorta supplying the left lower lobe. He underwent thoracotomy and was found to have extralobar sequestration on posterior aspect of Left lower lobe.

### Case 3

Mrs S. 48Yrs was admitted with history of recurrent episodes of haemoptysis for the last 10 yrs. She has recurrent episodes hemoptysis at interval of several years and were often massive. During the present hospitalization there was no positive physical findings and bronchoscopy showed there was bleeding from the lingular bronchus. CT thorax showed area of bronchiectasis in the lingula with softtissue density mass with contrast enhancement.

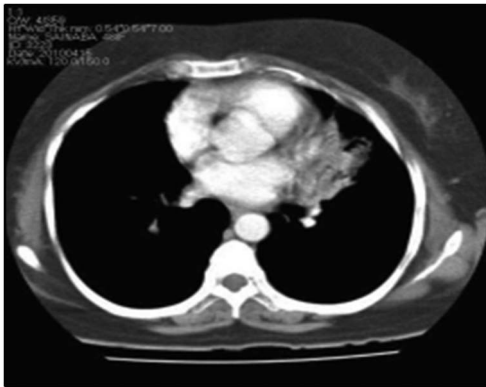


Figure 7. CT showed Area of bronchiectasis in the mass with contrast enhancing consolidation

Hemoptysis subsided and after one month patient developed massive hemoptysis again and she was considered for bronchial arterial embolisation therapy. The aortogram showed large vessel arising from the aorta just above the celiac trunk and going upwards piercing the left diaphragm to supply the lung tissue in the lingular segment.

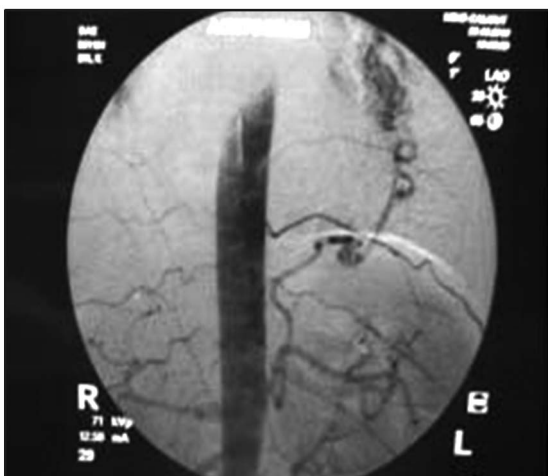

Figure 8. Showed large vessel arising from the aorta just above the celiac trunk and going upwards piercing the left diaphragm to supplying the lesion in the lingula.

These features were highly suggestive of an intralobar sequestration. Patient underwent bronchial arterial embolisation therapy which was successful in stopping the bleeding and occluding the anomalous artery.

### Case 4

Mr. S. 26Yrs presented to us with history of repeated episodes of fever, productive cough and occasional haemoptysis for the last 10 yrs. Clinical evaluation showed grade 1 digital clubbing. Auscultation showed crepitations in the left infrascapular area. He was found to have asymmetry of hands (one hand was smaller than other). CT thorax showed multiple cystic lesions in the posterior basal segment of the left lower lobe.

Some cystic spaces were also seen in the right lung. He underwent thoracotomy and the resection of involved segment left lower lobe. He was found to have large vessel piercing through the diaphragm and supplying the involved segment. This was found to be an extralobar sequestration. Following surgery patient made an uneventful recovery.

## DISCUSSION

Pulmonary sequestrations, like the various malformations of lung, bronchi and related vessels, are frequently diagnosed with the advent of CT thorax. On the chest x-ray film, sequestration can appear as a solitary mass<sup>4</sup> or poorly defined shadow, sometimes difficult to see. When infected, it is likely to appear as an area of pneumonia or bronchiectasis.<sup>5</sup> Some anomalous arterial branches are of significant diameter and length, for instance, those piercing the diaphragm. They present operative risk and death has been reported in which their presence was not determined prior to surgery.

Sequestrations are, in most instances (two-thirds of the cases) located in the dorsal part of the left lower lobe. This location for an unexplained shadow should be a major cause for suspicion of lobar sequestration

Detection of extralobar sequestration was facilitated previously by ordering an aortogram in evaluation of patients with bronchiectasis or mass lesions left lower lobe or posterior costophrenic recess in the past. However less invasive procedures like Multidetector CT scans with 3-dimensional reconstructions or magnetic resonance angiography reliably demonstrate the anomalous systemic arteries and allow a good planning for surgical therapy

Contrast enhancement of a pulmonary parenchymal

lesion in the relevant clinical setting also should raise the suspicion of sequestration in contrast enhanced CT thorax, which is routinely performed in cases presenting with haemoptysis

The study highlight the point that pulmonary sequestration should be considered in differential diagnosis of bronchiectasis, causes of haemoptysis.

## END NOTE

### Author Information

1. Dr. C P Rauf, Consultant Pulmonologist, Chest Hospital, Pavamani Road, Calicut – 673004.  
E-mail: [drraufcp@bsnl.in](mailto:drraufcp@bsnl.in)
2. Dr. Sangeetha E, Indian Medical Association, Anayara PO, Trivandrum
3. Dr. Deepak Kumar R, Indian Medical Association, Anayara PO, Trivandrum
4. Dr. Deepti Krishnan, Indian Medical Association, Anayara PO, Trivandrum
5. Dr. M Umar Majid, Indian Medical Association, Anayara PO, Trivandrum

**Conflict of Interest:** None declared

**Cite this article as:** C P Raufa, Sangeetha E, Deepak Kumar R, Deepti Krishnan, M Umar Majid. Extralobar and Intralobar Pulmonary Sequestrations - Report of 4 Cases. Kerala Medical Journal. 2012 Mar 30;5(1):18-21

## REFERENCES

1. Carter R. Pulmonary sequestration. *Ann Thorac Surg.* 1969 Jan;7(1):68–88.
2. Sato Y, Endo S, Saito N, Otani S, Hasegawa T, Sohara Y. A rare case of extralobar sequestration with hemoptysis. *The Journal of Thoracic and Cardiovascular Surgery.* 2004 Nov 1;128(5):778–9.
3. Saegesser F, Besson A. Extralobar and intralobar pulmonary sequestrations of the upper and lower lobes : Report of eleven cases, including one case of the scimitar syndrome. *Chest.* 1973 Jan 1;63(1):69–73.
4. Pappa KI, Anagnou NP, Elsheikh A, Bikouvarakis SS, Konstantinidou A, Salamalekis E. Congenital bronchopulmonary sequestration presenting as a thoracic tumor: a case report. *Eur J Gynaecol Oncol.* 2004;25(6):749–51.
5. Remy J. [Radiologic diagnosis of pulmonary sequestrations]. *Rev Mal Respir.* 2005 Jun;22(3):490–1; author reply 492.