

Female Urethral Leiomyoma: A Case Presentation

Vasudevan S^a, Anup GR^a, Thomas Daniel^a, Rajeevan^a

Department of Urology, Medical College, Trivandrum.*

ABSTRACT

Published on 30th December 2010

We present a case of urethral Leiomyoma of a female patient. A 35 years old lady presented with a mass which was protruding from the urethral meatus causing dysuria, frequency and urinary retention. Physical examination showed the presence of a mass protruding from the urethral meatus and filling the vaginal introitus. The patient was treated surgically and the symptoms completely disappeared. Histopathological examination showed leiomyoma of the female urethra. A review of literatures on the female urethra has revealed that the tumors of the female urethra are very rare. Having encountered such a lesion we think it should be reported.

Keywords: Urethral meatal mass, Leiomyomas, Endocrine dependent tumours

*See End Note for complete author details

INTRODUCTION

Leiomyoma are benign tumors of smooth muscle origin and rarely found in the urinary tract, with only 60 odd cases of urethral Leiomyoma reported in the literature. They may occur singly or in multiple numbers. It is more common in women between 30 and 50 years old. The first case was reported in 1894 by Buttner. There is a controversy about its dependency on estrogen hormones. Its diagnosis is made by Histopathological examination. We report a case of Leiomyoma of the female urethra with its clinicopathological characteristics.

In the genito-urinary tract, this type of tumor is generally found in the kidneys and less often in the bladder, prostate, ureters, urethra and testes. It may occur wherever smooth muscle is present. It is present in two types¹ Leiomyoma, composed of smooth muscle tissue, and² rhabdomyoma consisting of striated muscle. The malignant form of this mesenchymal tumor is the sarcoma.

CASE REPORT

A 35 years old lady with no history of past illness came to our OPD presenting a mass protruding from the urethral meatus for six months duration, associated with dysuria, frequency and retention of urine. No history s/o hormonal intake.

Physical examination showed hypospadias and a polypoid and rounded mass of size 4.5 cm in diameter,

protruding from anterior urethra, smooth surfaced, pink in color, firm in consistency & no pulsation (figure

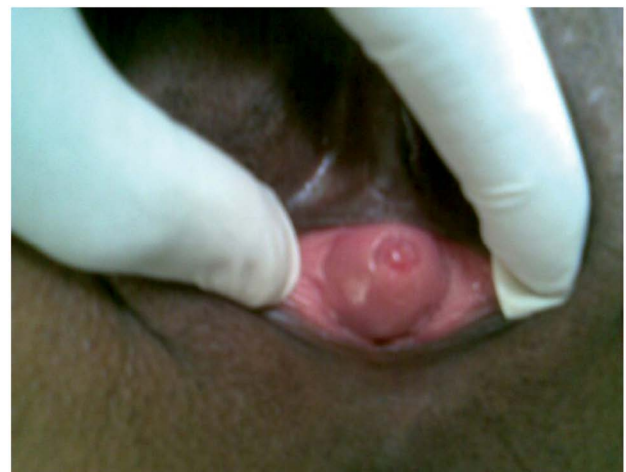

Figure 1. Mass protruding from urethral meatus

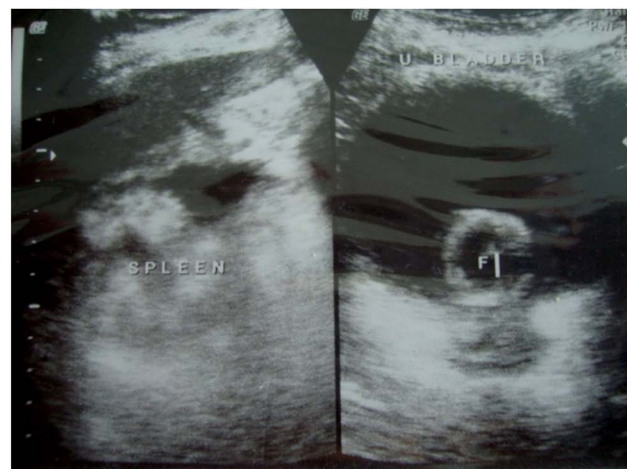

Figure 2. Ultrasound pelvis showing soft tissue density polypoidal lesion seen in anterior vaginal area arising from posterior urethral wall

Corresponding Author:

Dr. S Vasudevan, Additional Professor Urology, Medical College, Trivandrum, Kerala, India- 695011.
Phone: 9447124246. Email: periamana@gmail.com

1). There was an area of necrosis on the surface and it was neither tender nor did it bleed easily. All blood parameters were within normal limits.

Ultrasound examination (figure 2) of the pelvis done both in transabdominal and transvaginal modes showed the evidence of a soft tissue density polypoidal lesion of size 23x19 mm noted in the anterior vaginal wall with vascularity noted in the posterior urethral wall.

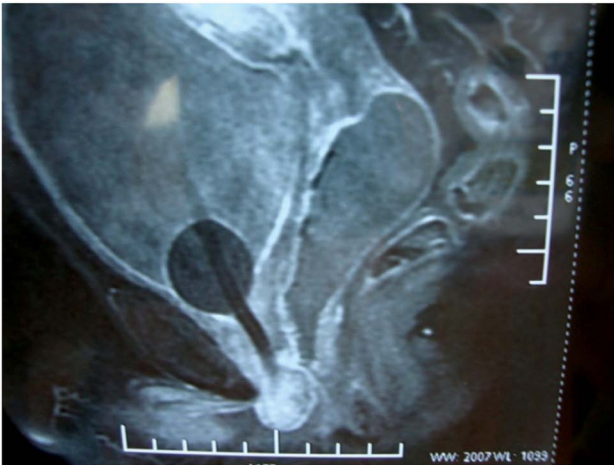

Figure 3. MRI Pelvis T2 weighted image STIR showing hyperintense image of tumour

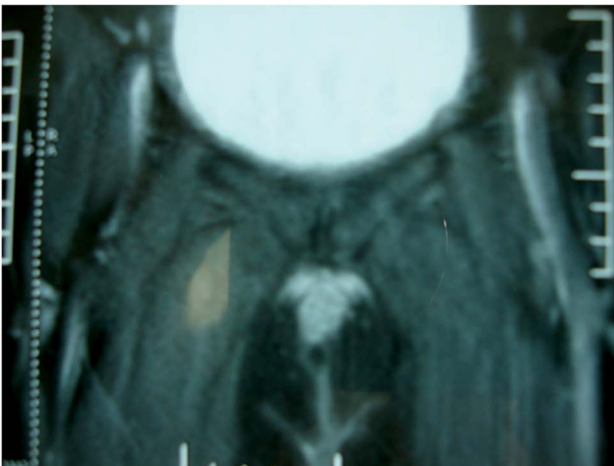


Figure 3. MRI Pelvis T2 weighted image showing hypointense muscle layer

MRI (figure 3 and figure 4) pelvis confirms the origin of the lesion. A nearly ovoid mass arising from the lower margin of urethra and bulging into the vaginal cavity minimally hyperintense on FSET2WI, STIR with mild to moderate enhancement. The lesion measures approximately 20x16x25 mm. The muscle layer appears hypointense on FSET2WI.

She was operated, tumor excised and specimen sent for histopathologic report and reported as Leiomyoma of female urethra (figure 5 and figure 6).

On follow up the patient was asymptomatic and within normal limits on urologic examination.

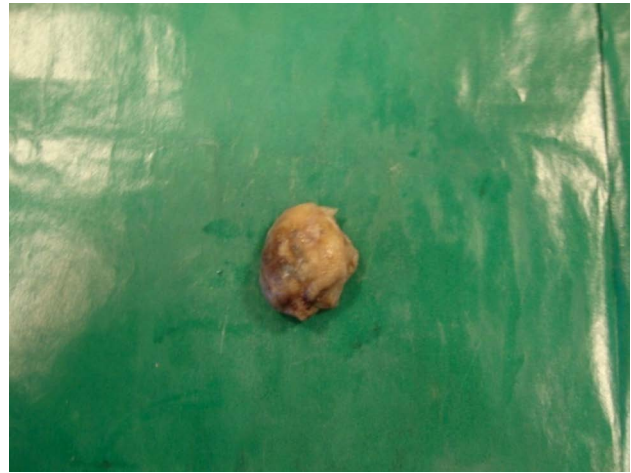

Figure 5. Gross view of the specimen

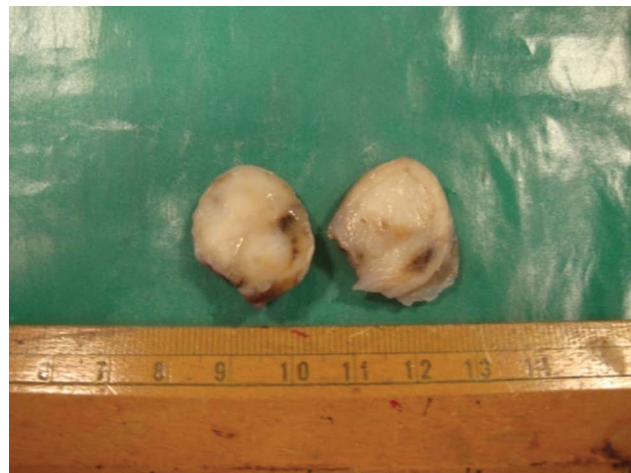

Figure 5. Cut section of the specimen showing tumour as solid encapsulated tissue

DISCUSSION

Leiomyoma is a benign tumor of mesenchymal origin, composed of smooth muscle cells found rarely in the urinary tract, the most common being the fibroid uterus. Leiomyoma are seen in the urinary tract in the decreasing order of frequency as the kidney, the bladder and the urethra.⁶ Leiomyoma are three times more common in women between 30 and 50 years of age.⁶ The size of the tumors ranged from 1 - 40 cm.^{5,6,7} The pathogenesis of Leiomyoma is unknown but its growth is probably endocrine dependent, with the growth patterns and size influenced by estrogen. The clinical presentation depends on the location and size of the tumor. Patient can be asymptomatic being the Leiomyoma may be an incidental finding during gynecological examination.

Common presenting symptoms are periurethral mass, urinary tract infection, hematuria, dysuria, poor stream and dyspareunia and even acute urine retention and acute renal failure.^{2,3,6,7}

The clinical diagnosis is made by history, physical examination, urethrocystoscopic examination and imaging studies like transvaginal ultrasonography, RGU, VCUG and MRI.^{2,3,5,6,7} The histopathologic examination will give the definite diagnosis, so also in this case. The other possible clinical diagnosis to be differentiated for urethral Leiomyoma may be thought off with clinical conditions such as urethral caruncle, papilloma, urethral diverticulum, ectopic ureterocele, fibrous polyp, Gartner's duct cyst, periurethral abscess, urethral carcinoma and other mesenchymal tumors.^{5,6}

The definitive treatment of urethral Leiomyoma is surgery as no reported recurrence.⁷ The operation techniques depend on the site of the tumor. In this case, we removed the tumor through incision of the posterior urethral wall. The prognosis of this tumor is excellent as malignant transformation has not been ever reported.^{1,6,7} The patient is asymptomatic post-operative on follow up 3 months.

Section through the tumor shows stratified squamous epithelium which becomes continuous with transitional epithelium. The transitional epithelium forms deep crypts in the supporting tissue. Around such crypts and in the supporting tissue is a diffuse infiltration by lymphocytes, plasma cells and occasional polymorphonuclear leukocytes. The epithelial cells are regular and basement membranes are well defined. The rest of the section is made up of a well circumscribed tumor nodule which is composed of spindle-shaped cells which resemble those of smooth muscle. The cells form whorls and bands which interlace with each other. The nuclei are quite regular in appearance and there is no evidence of any malignant tendency.

CONCLUSION

1. Leiomyoma of the female urethra is a benign mesenchymal tumor and are very rare.
2. The diagnosis is confirmed by histo-pathological study.

3. The definitive management is surgical.
4. The prognosis is excellent as no risk of malignant transformation.

END NOTE

Author Information

1. Dr. Vasudevan S, Additional Professor, Department of Urology, Medical College, Trivandrum.
2. Dr. Anup GR, Senior Resident, Department of Urology, Medical College, Trivandrum.
3. Dr. Thomas Daniel, Senior Resident, Department of Urology, Medical College, Trivandrum.
4. Dr. Rajeevan, Senior Resident, Department of Urology, Medical College, Trivandrum.

Conflict of Interest: None declared

Cite this article as: Vasudevan S, Anup GR, Thomas Daniel, Rajeevan. Female Urethral Leiomyoma: A Case Presentation. Kerala Medical Journal. 2010 Dec 30;3(4):128-130

REFERENCES

1. CORNELLA JL, LARSON TR, LEE RA, MAGRINA JF, KAMMERER-DOAK D. Leiomyoma of the female urethra and bladder: report of twenty-three patients and review of the literature. *Am J Obstetric Gynecol* 1997.
2. LEUNG YL, LEE F, TAM PC. Leiomyoma of female urethra causing acute urinary retention and acute renal failure. *J Urol* 1997. [PubMed]: <http://www.ncbi.nlm.nih.gov/pubmed/9334633>
3. LEE MC, LEE SD, KUO HT, HUANG TW. Obstructive Leiomyoma of the female urethra: report of a case. *J Urol* 1995.
4. LEIDINGER RJ, DAS S. Leiomyoma of the female urethra. A report of two cases. *J Reprod Med* 1995.
5. Jain R, Sawhney S, Bandhu S, Seth A. Leiomyoma of the female urethra. *Indian J Radiol Imaging [serial online]* 2000
6. A: Rodriguez Alonso, D. Perez Garscia, A. Nunez Lopez, et. All Leiomioma de uretra femeniana. Presentacio de caso. *Actas Urol Esp.* 24(9)2000.
7. Cheng C, Mac-Moune Lai F, Chan PSF: Leiomyoma of the female urethra: a case report and review. *J Urol* 1992