

# Isolated Sphenoid Sinus Inverted Papilloma

John Mathai

Department of ENT, Medical College, Kottayam\*

## ABSTRACT

Published on 29<sup>th</sup> June 2010

Isolated sphenoid sinus inverted papilloma is extremely rare. Its diagnosis and management is challenging because of the paucity of sinonasal symptoms and the inherent surgical risk associated with its anatomical location. Here we report a case of left sphenoid sinus inverted papilloma discussing its clinical and radiological features and endoscopic management.

**Keywords:** Inverted papilloma, Sphenoid sinus, Endoscopic excision

\*See End Note for complete author details

## INTRODUCTION

Inverted papilloma is a benign sinonasal tumor of ectodermal origin.<sup>1</sup>The most common site of origin is the lateral nasal wall. They can extend along the mucosa on to the adjacent paranasal sinuses. Rarely it can arise primarily in a paranasal sinus, usually the maxillary or ethmoid sinuses. Inverted papilloma arising in sphenoid sinus is exceedingly rare.

## CASE REPORT

A 52 yr old female presented to us with headache, left nasal bleed and nasal discharge of 10 years duration and left sided nasal obstruction of 4 years duration. Examination revealed a reddish mass arising from roof of left nasal cavity. Posterior rhinoscopy showed reddish mass filling upper 2/3<sup>rd</sup> of left choana. Examination of ear, throat, orbit and cranial nerves

were normal. CT scan nose and paranasal sinuses with contrast enhancement showed homogenous nonenhancing soft tissue density filling left sphenoid sinus with erosion of its anterior wall. Mass was seen extending into posterior part of left nasal cavity. Rest of the bony walls of sphenoid sinus was intact. [Figure-1] [Figure-2] Diagnostic nasal endoscopy showed reddish mass arising from left sphenoid sinus. Biopsy was taken and histopathologic examination proved to be inverted papilloma.

As CT scan with contrast enhancement suggested a non enhancing tumor we proceeded with endoscopic excision of mass under local anaesthesia. Anterior wall of left sphenoid sinus was found eroded. Rest of the bony walls of sphenoid sinus was intact. There was evidence of left posterior ethmoiditis which was also cleared. Post operative period was uneventful. Patient is now on endoscopic follow up.

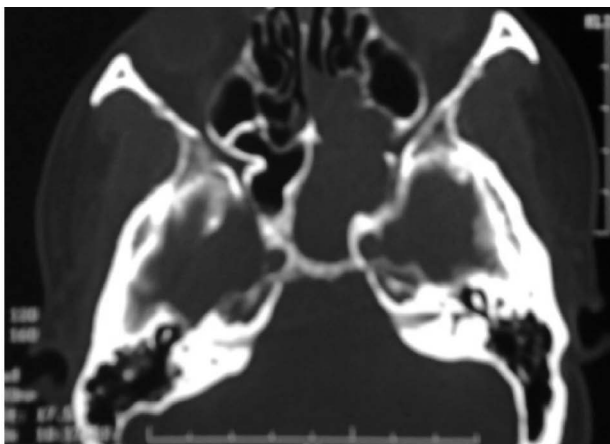


Figure 1. CT scan axial view showing mass (L) sphenoid sinus with anterior wall erosion

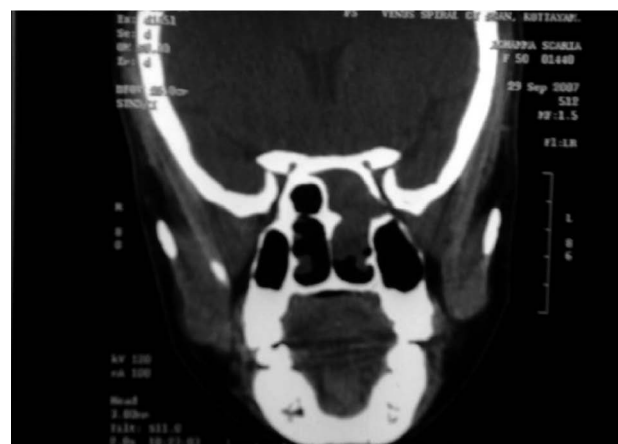

Figure 2. CT scan coronal view showing (L) sphenoid sinus mass extending into nasal cavity

### Corresponding Author:

Dr. John Mathai, Professor, Department of ENT, Medical College, Kottayam – 686008.  
Mob: 9447965010, E-mail : drjohnmathai@hotmail.com

## DISCUSSION

Inverted papilloma constitutes 0.5 – 4% of all sinonasal tumors. It is a benign tumor with potential for local invasion and rarely, malignant transformation. They belong to the group of sinonasal papillomas which constitute tumors arising from the ectodermally derived mucosa of sinonasal tract, the Schneiderian membrane and hence the name Schneiderian papilloma.<sup>1</sup> Etiology of inverted papilloma is still unknown. Proposed causes include allergy, chronic sinusitis, airborne pollutants, tobacco and viral infections.

Inverted papilloma are red or grey translucent masses usually arising from the lateral nasal wall.<sup>2</sup> They can grow along the mucosa extending to adjacent paranasal sinuses. They are typically unilateral but can present as bilateral mass when septal perforation should be ruled out. Rarely inverted papilloma can arise primarily in a paranasal sinus, usually in the maxillary or ethmoid sinuses. Inverted papilloma arising from sphenoid sinus is exceedingly rare.

The most common age of presentation is between 5<sup>th</sup> to 8<sup>th</sup> decade. Men are affected four times more often than women.<sup>3</sup> The clinical features depend on the site of involvement. They usually present with symptoms mimicking sinusitis. Clinical presentation of sphenoid sinus inverted papilloma is often nonspecific and insidious. Majority of patients present with headache. Diplopia and diminution of vision indicate invasion of orbital apex, cavernous sinus or internal carotid artery.

Histologically inverted papilloma exhibit markedly thickened squamous epithelial proliferation growing downward into underlying stroma, giving it an inverted growth pattern.<sup>4</sup> There are no reliable histologic feature that predict which papillomas are likely to become malignant. Moderate to severe epithelial dysplasia, surface keratinization and dyskeratosis are considered possible predictors of malignant transformation.

CT scan is considered the investigation of choice. Inverted papilloma present as unilateral mass with a lobulated surface in the region of middle meatus and extending to adjacent sinuses. Bony thinning and erosion are well demonstrated in CT scan.

The surgical significance of inverted papilloma is because of their tendency : 1) for local invasion and bone erosion, 2) to recur after surgical removal and 3) for malignant transformation. Recurrence can be minimized with better exposure and illumination with assistance of an endoscope. Malignant transformation in inverted papilloma ranges from 5- 10% and

most common type of malignancy associated with it is squamous cell carcinoma.

Complete surgical excision is the treatment of choice. The surgical approach and technique must be flexible and tailored to individual patient. Type of surgery depends on extent of tumor, number of previous surgeries, patient commitment to follow up and surgeons experience. The surgical modalities for sphenoid sinus inverted papilloma in practice are the open and endoscopic approaches. The open approaches include the sublabial transeptal approach of Cushing and the transetmoid approach via an external incision. Endoscopic surgery is an excellent procedure for treating patients who have limited disease of lateral nasal wall, anterior and posterior ethmoids, sphenoid sinus and medial maxillary wall.<sup>5</sup> Patients whose disease extend beyond these sites should be considered for an external approach with or without adjunctive endoscopic surgery. Advantages of endoscopic surgery are that it is less invasive, gives better illumination, better exposure of difficult access areas, greater tumor clearance and absence of facial scarring. Disadvantages are that it is not suitable for larger tumors, risk of orbital injury and CSF leak and inability to obtain an en bloc resection. Recurrence rate with endoscopic surgery (17- 27%) is comparable with that of external approaches. (4-35%)<sup>6</sup> Another advantage of endoscopic surgery is in the follow up of patient for any recurrence. For sphenoid sinus tumors with intracranial extension transcranial approach is preferred.<sup>7</sup>

## CONCLUSION

Management of sphenoid sinus inverted papilloma presents challenges because of its close anatomical relation to vital structures. Endoscopic resection affords the surgeon better visualization of tumor. Open approaches, with their attendant morbidity, add no advantage in this location. This case adds further support for endoscopic resection of inverted papilloma.

## END NOTE

### Author Information

Dr. John Mathai, Professor, Department of ENT, Medical College, Kottayam - 686008

**Conflict of Interest:** None declared

**Cite this article as:** John Mathai. Isolated Sphenoid Sinus Inverted Papilloma. Kerala Medical Journal. 2010 Jun 29;3(2):59-61

## REFERENCES

1. Christopher. D. M. Fletcher. Diagnostic Histopathology of Tumors. Third edn, vol- 1, Chapter 4, p 83-87
2. Yiotakis I, Psarommatis I, Manolopoulos L, Ferekidis E, Adamopoulos G. Isolated inverted papilloma of the sphenoid sinus. The Journal of Laryngology & Otology. 2001 Mar;115(03):227-30.
3. Rosai and Ackerman's surgical pathology, ninth edn, vol-1 chapter-7, p 83-87
4. Ringertz N. Pathology of malignant tumours arising in nasal and paranasal cavities and maxilla. Acta Otolaryngol 1938;27:31-42.
5. Stankiewicz JA, Girgis SJ. Endoscopic surgical treatment of nasal and paranasal sinus inverted papilloma. Otolaryngol Head Neck Surg. 1993 Dec;109(6):988-95.
6. Myers EN, Fernau JL, Johnson JT, Tabet JC, Barnes EL. Management of inverted papilloma. Laryngoscope. 1990 May;100(5):481-90.
7. Nishio S, Samoto K, Takeshita I, Matsumoto K, Matsushima T, Fukui M. Inverting papilloma of the sphenoid sinus: report of two cases. J Clin Neurosci. 2001 Mar;8(2):168-70.